

Analysis of 6 Cases of Stromal Sarcoma of the Breast

Yizi Cong
Juntian Liu
Zhilong Jia

No. 2 Department of Breast Cancer, Tianjin Medical University Cancer Institute and Hospital, Tianjin 300060, China.

Correspondence to: Juntian Liu
E-mail: ljt641024@yahoo.cn

Received December 24, 2008; accepted March 9, 2009.

E-mail: 2008cocrc@gmail.com
Tel (Fax): 86-22-2352 2919

OBJECTIVE To investigate the clinical and pathological characteristics, diagnosis and treatment of stromal sarcoma of the breast (SSB). **Methods:** The clinical and pathological data of 6 patients with SSB treated between 1954 and 2007 were retrospectively analyzed.

METHODS The clinical and pathological data of 6 patients with SSB treated between 1954 and 2007 were retrospectively analyzed.

RESULTS All patients were female and one was menopausal. The median age of the patients was 39 years old (range, 20-55). All cases had a history of a palpable mass. The tumor rapidly augmented in a short time period in 3 patients. One patient had discontinuous pain and 3 patients had masses located in the upper outer quadrant of the breast. The median tumor radius was 6.0 cm (range, 3-15 cm). According to the AJCC breast cancer staging standard (6th edition), 1 case was of stage IIA, 2 cases were of stage IIB, 2 cases were of stage IIIB and one case couldn't be staged. Four patients were initially treated by excising the tumor and then undergoing mastectomy or modified radical mastectomy after recurrence. Radical mastectomy was suitable for those with pectoralis major muscle involvement. Two patients received simple mastectomy, 2 patients underwent radical mastectomy and another 2 patients received modified radical mastectomy. After surgery, all patients were identified as SSB through pathology, with focal ossification in one case and mucinous degeneration in another one case. Four patients who underwent axillary lymph node dissection did not have lymph node metastases. Three patients received chemotherapy after surgery. After a median follow-up time of 36.5 months (8-204 months), 4 patients had recurrence after local excision and 3 patients had recurrence more than 2 times with a median time to recurrence of 2.5 months (1 to 4 months) after surgery. One patient had lung metastases at 7 months after the initial surgery and the other 5 patients were alive without disease at the end of the follow-up period.

CONCLUSION SSB is difficult to diagnose preoperatively and is characterized by its tendency to recur locally. To obtain negative margins, wide local excision or mastectomy must be performed. Axillary lymph node dissection is not mandatory. The roles of adjuvant chemotherapy and radiotherapy have still been controversial.

KEY WORDS: breast neoplasm, stromal sarcoma, recurrence, therapy.

Copyright © 2009 by Tianjin Medical University Cancer Institute & Hospital and Springer

Introduction

Stromal sarcoma of the breast (SSB) is a malignant tumor that is involved in pure lobus intermedius without involvement of the epithelium of the breast. The related report about SSB is rarely found

in China and overseas^[1]. The degree of malignancy of the tumor is high, and the preoperative diagnosis is difficult. The relapse of the disease is frequently seen after local excision. The efficacy of postoperative adjunctive therapy has been unclear^[2]. To improve the ability of the professionals in accurate diagnosis of SSB, the data of the 6 patients with SSB, admitted to our hospital from May 1954 to September 2007, were retrospectively analyzed so as to outline the clinicopathologic characteristics, the ways of diagnosis and prognosis of the disease, combined with reviewing the relative literature.

Materials and Methods

General data

All the 6 patients in our group were female, with the median age of 38 years (range, 20-55). Based on the standard (6th Ed) of the breast cancer staging issued by American Joint Commission for Cancer Staging (AJCCS), 1 case was in Stage IIA, 2 in Stage IIB, 2 in Stage IIIB, and 1 failed to achieve the staging criterion. Four of the 6 patients with relapse were admitted to our hospital after local excision of the tumor. Among the 6 cases, 2 of them had the lesion located at left breast, and the other 4 at right breast. All the lesions were unilaterally present. The lesion at the upper outer quadrant (UOQ) was found in 3 cases, the mid-upper outer quadrant in 1, the upper inner quadrant (UIQ) in 1 and the central area in 1, with a course of disease ranging from 2 months to 3 years. Mammary swellings were found as the initial symptom in all 6 patients. Rapid growth of the tumor within several months after discovery occurred in the 3 cases and one of them had a discontinuous pain. No nipple discharge was found in all the cases. The median diameter of the tumors was 6.0 cm (3-15 cm), with a hard texture or inhomogenous hardness, and blurred boundary from the normal tissue. The lump was limited mobility in 4 cases and 1 was better through palpation. Concurrent scytitis in mammary areola area occurred in 17 cases, with a stellate ganglion (Fig.1). The lesion adhering to the chest wall was found in 1 case, and a 0.6 cm × 0.5 cm axillary lymph node was found and removed in another patient during the surgery. The clinicopathologic data of the 6 patients are showed in Table 1.

Clinicopathologic examinations

General physical examinations were conducted on the patients after admission, including the routine examinations of blood, urine, hemagglutination, and the biological and epidemiological analyses. Auxiliary examinations included X-ray examination of the chest, electrocardiogram (ECG), molybdenum target of the breast, ultrasonic inspection of abdominopelvic cavity and fine needle aspiration biopsy, etc. Routine pathologic H&E chromoscopy was conducted for analyzing postoperative samples. The literature was consulted for diagnostic criteria^[1-3].

Treatment methods

Surgical treatment was conducted in all the cases. Local excision of the tumor was performed as initial treatment for the 4 of the patients. The mastectomy or modified radical operation was conducted when the recurrence occurred after the local excision in the 4 patients. Radical excision of the breast was carried out for those whose major pectoral muscle was involved, and the skin grafting was performed on one patient whose surgical incision needed. Finally, simple mastectomy was performed in 2 cases, radical mastectomy in 2 including 1 with skin grafting, and modified radical mastectomy in the other 2, based on the tissue and the axillary lymphatic involvement of the tumor at the surgery. The surgical procedures were completed smoothly. The patients had satisfied postoperative recovery and no severe complication. After the surgery, the adjunct therapy was given to 3 of the cases, and the therapeutic regimens included as follows: ifosfamide + pharmorubicin, cyclophosphamide + adriamycin + 5-Fu, and cyclophosphamide + dacarbazine + pharmorubicin + vincristine. Six cycles of the chemotherapy were performed in the 3 cases, and no obvious complaint was raised from the patients. Radiotherapy was not conducted in any of the patients.

Results

Findings of the examinations

No apparent abnormality was found in the examinations of the blood and the urine, biochemistry, epidemiology, and the chest X-ray. The ECG showed that ST-T change was seen in 1 case, and the propranolol test (+), sinus irregularity and clockwise rotation were seen in another 1. The rest of the cases had normal results of their examinations. Type-B supersonic examination was conducted on the 2 cases, which indicated that the tumor presented a low echo-level reflex zone, with obscure boundary and inhomogeneous internal echo. The examination of color Doppler flow imaging (CDFI) showed that there was or no obvious signal of blood flow in 2 cases, among which, 1 was highly suspected as an adenofibroma which was not excluded the possibility of the cystosarcoma phyllodes (CSP), and the other case was diagnosed as the intumescent malignant tumor in her left breast. Molybdenum target examination was conducted on the 2 cases, and it showed the tumors with a smooth or clear margin, and uniform density. One of the 2 patients was diagnosed by molybdenum target examination as the multiple benign neoplasm on her left breast and the other was the giant tumor, cancer or sarcoma. Two cases were diagnosed as soft tissue sarcomas by the bodkin aspiration biopsy and highly suspected as phyllodes tumors, or stromal sarcomas (SS), and 1 of them was diagnosed as malignant tumor which was suspected as sarcoma.

Pathological outcomes

The initial pathologic diagnoses of the 6 patients were

Table 1. The clinical feature, treatment and prognosis of 6 patients with SSB.

Case	Age, years	Tumor (cm)	Site	Symptoms and signs	TNM staging	Previous local excision	Mode of surgery	Pathological results	Chemotherapy	Relapse & metastasis	Follow-up (mon)
1	20	8 × 8	Central area of right breast	Rapid growth of the tumor, with dark purple on surface of the skin and without pain; the tumor at palpation was lobulated, with a hard texture or inhomogeneous hardness, and blurred boundary from the normal tissue, the lesions adhering to the skin and chest	T4N0M0 Stage IIIB	Relapse after 2 local resections of the tumor	Radical resection	Mucinous degeneration of stromal sarcoma, In: 0/8	None	Metastases in bilateral lungs 7 months after surgery	8
2	35	3 × 2	UIQ of right breast	Rapid growth of the tumor, without pain; a 5-cm radial incision at UIQ	T2N0M0 Stage IIA	Relapse after 2 local resections of the tumor; an intra-muscular capillary tumor	Radical resection	Stromal sarcoma, In: 0/62	(IFO + EPI) × 6	None	12
3	35	Failure of achieving the staging criteria-on	MUOQ of right breast	A 5-cm transverse incision at MUOQ of right breast	TxN0M0	Relapse after 2 local resections of the tumor; a fibrosarcoma of the breast	Excision of total breast	Stromal sarcoma	None	None	204
4	41	15 × 13	UOQ of left breast	Rapid growth of the tumor, with discontinuous dull pain and blurred boundary, fixation, scytitis of whole breast, a 5×6-cm ulcer at upper left quadrant, a stellate ganglion	T4N0M0 Stage IIIB	None	Excision of total breast	Stromal sarcoma	(CTX + DTIC + ADM + VCR) × 6	None	41
5	46	3.5 × 3	UOQ of left breast	No pain and nipple discharge were found 2 months after discovery of the tumor; The surface of tumor was smooth at palpation, with a hard texture and a better mobility, and a 0.5×0.6-cm axillary nodes	T2N1M0 Stage IIB	None	Excision of total breast + lower armpit	Stromal sarcoma with focal ossification, In: 0/22	CAF×6	None	60
6	55	6 × 6	UOQ of right breast	No pain and nipple discharge were found; The lump had a hard texture, a blurred boundary and a poor mobility	T3N0M0 Stage IIB	Relapse 4 months after excision of the tumor	Excision of total breast + lower armpit	Stromal sarcoma of low malignancy, In: 0/10	None	None	32

as follows: 2 diagnosed as the fibro-sarcoma (FSa) in other hospital, 1 CSP and 1 intramuscular capillary hemangioma in other hospitals, and 2 SS in our hospital. It was confirmed by postoperative pathological examination that all cases were SSB. It was seen by macroscopy that the cut surface of tumor was greyish, with exquisite texture or inhomogeneous hardness, and had a visible boundary, but without a thin capsule around the tumor like the benign tumors. The result of microscopic examination showed that the tumor was composed of spindle-shaped, rounded and immature cells, and caryomitosis was obviously seen. In the 6 cases, one patient's tumor was stromal sarcoma-like SS (Fig.2), and one's was SS accompanied with focal ossification, and one's with mucous degeneration. Axillary lymphadenectomy was conducted in 4 patients, and no lymphatic metastasis was found (0/62, 0/10, 0/22, 0/8).

Follow-up

The median time of post-operative follow-up was 36.5 months (range, 8-204), with 1 patient lost during the follow-up period. Local resection of the SS was performed in 4 patients, and relapse occurred in all the 4 patients within several months after the surgery. The median time of the initial recurrence was 2.5 months (range, 1-4). Of the 4 cases, 2 or more times of relapse took place in 3 patients, and a simple mastectomy or radical mastectomy was performed on the 3 after the relapse. Bilateral pulmonary metastases oc-

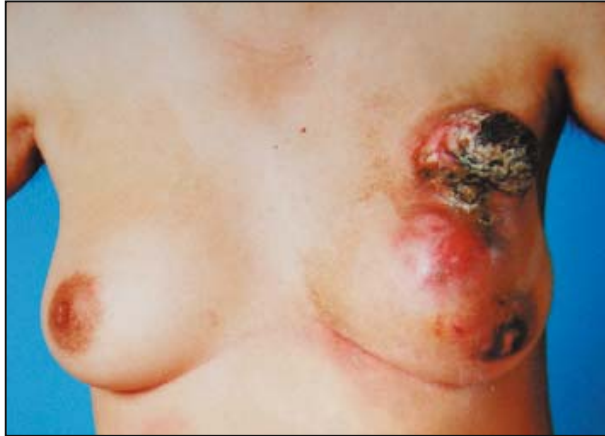

Fig.1. The tumor at the upper outer quadrant of the left breast, with skin ulcer (Case 4).

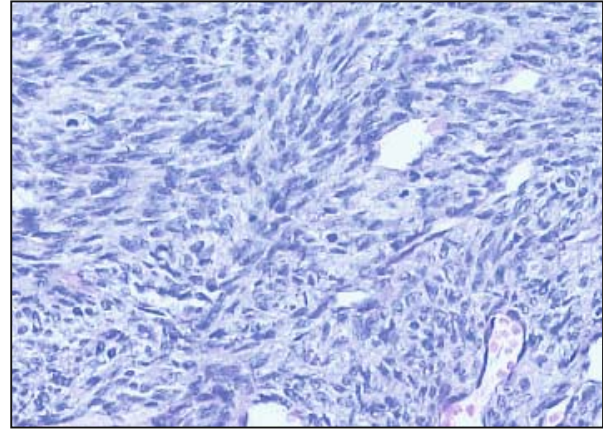


Fig.2. SSB presenting a stromal-sarcoma-like form (fibrosarcoma), H&E $\times 200$ (Case 4).

occurred in 1 of the 6 patients seven months after the surgery, and then the family members suggested stopping the treatment for the patient that was the one who was lost for the follow-up after that. The other 5 patients survived free of the disease till the date we collected the data of the patients. In the 6 patients, the longest time of disease-free survival was 17 years.

Discussion

SSB was initially reported by Berg et al.^[4] in 1962. He then selected 25 patients included those with SS, malignant fibrous histiocytoma (MFH) and liposarcoma. Later, Rosen and Callery proposed that, based on the construction features of the breast tissue, the real stromal sarcoma originated from the sarcoma of special stroma with a hormone response in the lobule of mammary gland. At present, the definition of SSB is the tumor that is composed of pure lobus intermedius and short of epithelium, and the source of the cells can not be verified by histio-cytopathology, exclusive of all the identifiable breast sarcomas (BS), such as angiosarcoma, liposarcoma, stromal sarcoma and MFH, etc.^[3] The component may include fibers, mucoid and liposarcoma-like compositions, or the mixture of the above-mentioned components, thus it is called the stromal sarcoma. Based on the 2003 WHO New Classification of Fibro-Epithelial Tumor, the SS around low level ductus originates from the mesenchyma around the ductus, and is composed of the open ductus and the coat-sleeve like spindle cells around the ductus^[1].

SSB is rare, and the cause of the disease is not clear. It was reported that the SS is related to the use of the silica gel prosthesis in breast swelling operation^[5]. It was shown in other evidence that chest-wall exposure to the radiation may bring about BS in patients with breast cancer or other malignant tumors, but most of the BS is angiosarcoma. The age of onset of SSB patients

is usually ranged from 48-49 years^[1,6]. It is rare in the males. The main clinical manifestation is the gradually increased and painless tumor, usually with a big size^[7], i.e., 5-6 cm in diameter. The tumor is tuberous, or lobulated, and hard in texture, with a solid cystic manifestation because of the occasional hemorrhagic necrosis which is frequently seen at UOQ. It might also be involved in the total breast, the pectoral muscle, and even the chest wall. At the surface of the tumor in the breast, the dermatocic introcession and rebound phenomenon are rare. The most commonly-seen symptom includes direct invasion and the hematogenous metastasis, and the lymphatic metastasis is rare, which occurred at the advanced stages of the lesion^[2]. All patients in our group were female, with a median age of 38. Of all the patients, the lesion at UOQ was found in 3 cases (50%). The maximum median diameter of the tumor was 6.0 cm. Axillary lymphadenectomy was conducted in 4 patients, however, no lymphatic metastasis was found confirmed by the pathological examination. Pulmonary metastasis occurred in 1 patient.

The results of the microscopy demonstrate that SSB is composed of malignant lobus intermedius, however, its shape is greatly varied. Some present a well-differentiated SS, and some are composed of undifferentiated lobus intermedius, such as spindle-cell sarcoma, and mucoid and liposarcoma-like components, with a frequently-seen karyomitosis. Some even have a variform cell constituent, including spindle cells, tumor giant cell, focal ossification and chondrometaplasia^[1]. Immunohistochemical staining showed Vimentin is positive, and the MNF16, CK-7, CK-20, CD31, CD34, CD68, SMA, desmin and S-100 proteins are all negative^[7]. Differential diagnosis mainly identify the SSM from CSP, highly/hyper-anaplastic, medullary cancer, and other kinds of spindle-cell sarcoma. Wide-ranging sampling and immunohistochemistry help identify the disease, and the major difference between the SSB and the other kinds

of tumor mentioned above is as follows. There is still epithelium in CSP, and a typical medullary cancer zone in poorly-differentiated medullary cancer can be found. The stain results of Keratin and EMA are positive, and that of SS is negative^[3]. Comparing the construction of SS and SSB, the component of SS is simple, but the textural form of SSB is complicated and greatly varied. Besides the SS-like components, there are many kinds of undifferentiated mesenchymal composition. Diagnosis of SSB by type-B ultrasonic and molybdenum target examinations is usually difficult, because it is rather hard to tell SSB from CSP. Sarcoma can be easily diagnosed using bodkin aspiration biopsy whose result is of important guidance in treating SSB.

Surgical excision is a main means, and the wide local excision, or simple mastectomy can be used in SSB treatment. Axillary lymphadenectomy is usually unnecessary^[8,9]. Frequent recurrence occurs after local resection. In our group, recurrence occurred in 4 patients several months after surgery, and 3 of the 4 even underwent twice more relapses. Therefore, ensuring a negative incised margin is extremely important. Salvage treatment after relapse includes re-excision or mastectomy of total breast. In our patients, mastectomy was conducted in 2, radical mastectomy in 2, and modified radical mastectomy in another 2. At present, the role of postoperative adjunct therapy remains controversial. Similar to the treatment on the other sarcomas, recommended postoperative chemotherapeutic regimens include idarubicin and ifosfamide. Three of the 6 patients in our group, received postoperative chemotherapy including cyclophosphamide and adriamycins of the regimen. The median follow-up time was 41 months, and all patients, except one, survived free of disease. Few reports demonstrated that postoperative chest-wall radiotherapy may achieve a better effect in control of local recurrence of the tumor, but it has no effect on the long-term survival^[10]. Radiotherapy can be performed for the patients with a tumor diameter of over 5 cm, higher histological grade or a positive incised margin. Nevertheless, no radiation therapy was conducted in the 6 cases of our group. For the patients with advanced pulmonary metastasis, radiotherapy may become an effective therapeutic tool^[11]. Since hormone receptor of BS is not expressed, endocrine therapy is ineffective.

Based on the reports issued overseas, the 5-year survival rate of the BS patients ranges from 49%–66%^[8,9], while reports from Chinese authors indicate the rate is 66.7%^[12]. The survival rates of the BS patients are similar to those of other sarcomas, however, the 5-year disease-free survival rate is very low, i.e., 33%–52%. And in most of the cases, local recurrence occurred 15 months after surgery^[8]. Recent studies confirmed that BS, excluding angiosarcoma, share the same prognosis with malignant phyllodes tumor^[13]. Since the number of SSB cases is less in previous reports, no individual

prognostic analysis has been made. The grade, size and lymphatic status of tumors are the prognostic indicators of the patients, and negative incised margin is the most important prognostic factor. In our group, the patient of 20-year old of age with the tumor of 15 cm × 13 cm at relapse, was diagnosed as SS with mucinous degeneration, and developed bilateral pulmonary metastases 7 months after surgery, suggesting the tumor size, patient age, and pathologic types are the prognostic indicators of the SSB patients.

References

- 1 Li SL. Ed. *Oncology of the breast*. Beijing: Scientific and Technical Documents Publishing House, 2007; 123.
- 2 Hefny AF, Bashir MO, Joshi S, et al. Stromal sarcoma of the breast: a case report. *Asian J Surg* 2004; 27: 339–341.
- 3 Jayaram G, Gan SK, Yip CH. Fine needle aspiration cytology of stromal sarcoma of the breast. *Pathology* 2007; 39: 172–174.
- 4 Berg JW, Decrosse JJ, Fracchia AA, et al. Stromal sarcomas of the breast. A unified approach to connective tissue sarcomas other than cystosarcoma phyllodes. *Cancer* 1962; 15: 418–424.
- 5 Kobayashi S, Iwase H, Karamatsu S, et al. A case of stromal sarcoma of the breast occurring after augmentation mammoplasty. *Gan No Rinsho* 1988; 34: 467–472.
- 6 Kaminski DL, Taylor HB. Stromal sarcoma of the breast. *Mo Med* 1972; 69: 672–674.
- 7 Lipshy KA. Image of the month. Stromal cell sarcoma of the breast. *Arch Surg* 2005; 140: 95–96.
- 8 Lum YW, Jacobs L. Primary breast sarcoma. *Surg Clin North Am* 2008; 88: 559–570.
- 9 Bousquet G, Confavreux C, Magne N, et al. Outcome and prognostic factors in breast sarcoma: A multicenter study from the rare cancer network. *Radiotherapy and Oncology* 2007; 85: 355–361.
- 10 Pandey M, Mathew A, Abraham EK, et al. Primary sarcoma of the breast. *J Surg Oncol* 2004; 87: 121–125.
- 11 Tochika N, Kumon M, Ogawa Y, et al. Stromal sarcoma of the breast with lung metastasis successfully treated by radiotherapy: report of case. *Surg Today* 2000; 30: 282–285.
- 12 Xin ZF, Wang ZH, Yao SG. Analysis of 34 cases with mastosarcoma. *Zhongguo Zhongliu Linchuang* 2002; 29: 877–880 (Chinese).
- 13 Confavreux C, Lurkin A, Mitton N, et al. Sarcomas and malignant phyllodes tumours of the breast—A retrospective study. *Euro J Cancer* 2006; 42: 2715–2721.