

## Clinical Research of a Modified Midfacial Degloving in a Maxillectomy (with a Report of a Typical Case)

Yuanqing Zhao<sup>1</sup>  
Jialiang Guo<sup>1</sup>  
Yongtuan Li<sup>2</sup>

<sup>1</sup> Department of Otolaryngology-Head and Neck Surgery, Tianjin Teda Hospital, Tianjin 300457, China.

<sup>2</sup> Department of Otolaryngology-Head and Neck Surgery, Qingdao Municipal Hospital, Qingdao 266011 Shandong Province, China.

Correspondence to: Yuanqing Zhao  
E-mail: Zhaoyq101@sohu.com

Received February 6, 2007; accepted March 6, 2008.

CJCO <http://www.cjco.cn>  
E-mail: 2008coccr@gmail.com  
Tel (Fax): 86-22-2352 2919

**OBJECTIVE** To investigate the feasibility of employing a modified midfacial degloving in maxillectomy.

**METHODS** Eight patients with carcinoma of the maxillary sinus underwent a modified midfacial degloving operation. The tumors were classified according to the 2002 AJCC system. The TNM staging of the cases was as follows: 1 T<sub>4a</sub>N<sub>0</sub>M<sub>0</sub>, 2 T<sub>3</sub>N<sub>0</sub>M<sub>0</sub> and 5 T<sub>2</sub>N<sub>0</sub>M<sub>0</sub>. Of the 8 cases, 1 patient underwent extended maxillectomy; exenteration of the orbit; tumorectomy of the sphenomaxillary and infratemporal fossae. Two patients received a total maxillectomy, and 5 a partial resection of the maxilla. Postoperative pathological report: 4 well-differentiated squamous carcinoma, 2 moderately-differentiated squamous carcinoma, 1 mucoepidermoid carcinoma and 1 adenoid cystic carcinoma.

**RESULTS** A modified midfacial degloving operation can sufficiently expose a field of operation, resect the tumor within a safe margin, and leave no facial cicatrices. One patient died of intracranial metastasis 8 months after operation. We observed no recurrences or metastasis in other patients during the period of follow-up.

**CONCLUSION** The major advantages of employing the modified midfacial degloving in maxillectomy is that a facial incision can be avoided. It has an advantage of minimal invasive surgery.

**KEY WORDS:** maxilla neoplasm, surgery, operation, midfacial degloving operation, maxillectomy.

Copyright © 2008 by Tianjin Medical University Cancer Institute & Hospital and Springer

### Introduction

Important considerations for successful removal of a tumor in the nasal sinuses are a sufficiently exposed field of operation, resecting the tumor thoroughly and achieving satisfactory cosmetic results. The traditional *modus operandi* is a nasal approach, but facial cicatrices will remain. In 1974 Casson initiated a midfacial degloving procedure aimed at providing a new incision which is much broader than the nasal approach<sup>[1]</sup>, leaving no facial scarring. It has been mainly used for space occupying-lesions in the median line of the nasal cavity and nasal sinuses. From 2003, we used a modified midfacial degloving operation to treat 8 patients with carcinoma of the maxillary sinus. The results have been effective and satisfactory as noted in the following report.

### Patients and Methods

#### Patients

Of the 8 patients, there were 7 males and 1 female, with an average

age of 53 years (ranging from 46 to 65 years). The lesions of 6 people were located on the left and 2 on the right. The main symptoms were bloody nasal discharge or pus, facial formication, aching pain and so on. CT examinations of all the patients demonstrated a dense mass in the maxillary sinus, with 1 case showing an absence of the posterior and lateral wall of the maxillary sinus. The soft tissues expanded outwards, infiltrated into the sphenomaxillary and zygomatic fossae and intruded into the orbit. Four cases suffered from destruction of the alveolar process, and 7 destruction of the paries medialis maxillaris. All of the subjects received a definite diagnosis by pathology before operation. Four cases were well-differentiated squamous carcinoma, 2 moderately-differentiated squamous carcinoma, 1 mucoepidermoid carcinoma, and 1 adenoid cystic carcinoma. Preoperative radiotherapy was applied at 60 Gy and postoperative radiotherapy administered at 50 Gy by a linear accelerator.

### **Surgical procedure**

The supine patients were given general anesthesia through tracheal intubation. Incisal opening: *i*) The mucoperiosteum was cut open at 0.5 cm distance from the labiogingival groove by an electrical surgery unit, transected up to the maxillary tubercle and anterior to the cynodont on the normal side. The soft tissues were separated to the infraorbital margin on the operative side and to the apertura piriformis at the opposite side, then the anterior nasal spine was exposed. *ii*) The bottom of the nasal vestibule was cut through the incision between the anterior extremity of the nasal septum and columella nasi. *iii*) The bottom of the nasal vestibule was incisioned: along the inferior margin of the apertura piriformis (equivalently the bottom of the nasal vestibule), cut from the terminatio of the superior incision to the wall of the nasal alar cartilage, creating a C-shaped incision. The lateral mucous of the nasal cavity was cut along the exterior margin of the apertura piriformis. Compared to the toroid incision of a classical midfacial degloving operation, it omitted the incision between the lateral cartilage of the nose and nasal alar cartilage. The upper lip, bilateral alae nasi and external nasal pyramid from the inferior bone wall were separated. A retractor was used to divulse all of this upwards as a entirety. Then the structure of the midfacial bones can be exposed sufficiently. According to the position of the tumor and the operation requirements, extended maxillectomy or partial maxillectomy could be performed. The ambipedicled mucosa flap was made by the lateral mucosa of the nasal cavity, and the anterior border of this flap up with the nasal vestibule was sewed. Stenosis of the nasal vestibule can be prevented if the posterior extremity is not sewed up. The other incisions were closed with apposition sutures. The operative cavity was filled with gelatin sponges and iodoform gauzes.

### **Typical example**

A male patient, 56 years of age came into the hospital because of a bloody nasal discharge, and pain on the left side of his face and outer canthus. CT showed there was a swelling of lymphoid nodes in the II cervical region, and an absence of the posterior and lateral wall of the maxillary sinus. The soft tissues expanded outwards, infiltrated into the sphenomaxillary and zygomatic fossae and intruded into the orbit. Pathologic staging was T<sub>4a</sub>N<sub>0</sub>M<sub>0</sub>.

The patient underwent the following procedure: a modified midfacial degloving operation; temporary interruption of the external carotid artery; extended maxillectomy plus exenteration of the orbit; tumorectomy of the sphenomaxillary and infratemporal fossae; selected neck dissection. A lateral cervical incision and temporary interruption of the external carotid artery were conducted first to decrease hemorrhage. At the same incision, selected neck dissection was applied in II and III regions.

We adopted a modified midfacial degloving incision and retained the hard palate mucosal flap which had a posterior pedicle to sufficiently expose the field of operation. The tumor had invaded into the orbit, involved the fat layer of the orbital cavity, and had encroached upon the sphenomaxillary and infratemporal fossae through the posterior and lateral walls of the maxillary sinus. The zygomatic arch, frontal process of the zygomatic bone, processus frontalis maxillae and linea mediana of the hard palate were cut off using an electric saw and the tuber maxillae and pterygoid process removed by a chisel. The anterior part of the infratemporal fossa, and the tumor in sphenomaxillary fossa were separated and resected, and bleeding was stopped by electric coagulation. The mucosa of the blepharal fornix to the orbital periosteum was resected, the orbital contents separated and the orbital apex transfixed and cut off. The field of operation was covered with spongia gelatinosa, smeared with biogel and plugged with iodoform gauzes. Postoperative pathological reports demonstrated a well-differentiated squamous carcinoma, without the malignant cells involving the cross striated muscles around the eyeballs. Reactive hyperplasia developed in the lymphoid nodes of the left II and III regions. Immune chemistry reported CK (+), PCNA (+) and CK10 (+). Preoperative radiotherapy at 60 Gy and postoperative radiotherapy at 50 Gy was administered by linear accelerator. Follow-up to now, has shown no recurrences or metastases.

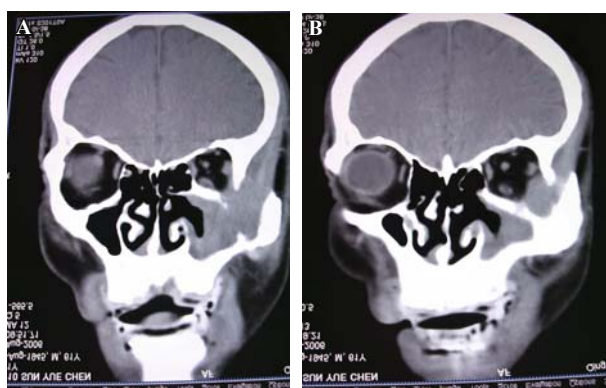
### **Results**

According to the TNM Staging of the American Joint Commission for Cancer (AJCC)<sup>[2]</sup>, the clinical stages and the surgical procedures are shown in Table 1.

After the operation, all of the patients had different levels of facial engorgement, which faded within 5 days.

**Table 1. Clinical stages, surgical procedures and follow-up results of 8 maxillae neoplasms.**

Stage	No.	Surgical procedure and follow-up results
T <sub>4a</sub> N <sub>0</sub> M <sub>0</sub>	1	Modified midfacial degloving operation; temporary interruption of the external carotid artery; extended maxillectomy; exenteration of the orbit; tumorectomy of the sphenomaxillary and infratemporal fossae; selected neck dissection. Still alive without recurrence or metastasis.
T <sub>3</sub> N <sub>0</sub> M <sub>0</sub>	2	Modified midfacial degloving operation; total maxillectomy. One patient underwent resection of the hard palate, and accepted another operation after 15 months because of a recurrence. One case died of intracranial metastasis 8 months after operation. The others are still alive without recurrence or metastasis.
T <sub>2</sub> N <sub>0</sub> M <sub>0</sub>	5	Modified midfacial degloving operation; partial resection of the maxilla. Still alive without recurrence or metastasis.



**Fig.1. A, There was an absence of the posterior and lateral walls of the maxillary sinus. The soft tissues expanded outwards and infiltrated into the sphenomaxillary and zygomatic fossae; B, The soft tissues invaded into the orbit through the inferior orbital fissure.**

The gauze was removed fractionally from the operative cavity after 48 h. Stitches were taken out after 7 d and the incisions healed quickly. Up to the present, follow-up has shown no stenosis of the nasal vestibule, 4 slight facial fallings, and 2 open rhinolalia.

**Discussion**

The approach in a traditional maxillectomy involves a nasal lateral incision. This sufficiently can expose the field of operation, but facial cicatrices will remain. The modified midfacial degloving process avoids facial incisions, but can this method sufficiently expose the field of operation for a maxillectomy or an extended maxillectomy? For this reason, we researched and adopted a modified midfacial degloving operation for treating malignant tumors of the maxillary antrum.

A classical midfacial degloving operation includes a bilateral Caldwell-Luc incision, a transfixid incision of the columella nasi, a bilateral intercartilagenous incision, and a bilateral arc incision of the nasal vestibule. This method will leave an unwanted maxillofacial wound because of the large operative area<sup>[3]</sup>. The tumors of the nasal cavity and (or) nasal sinuses are generally located at one side, besides the bilateral lesions, the intercartilagenous incision and arc incision of the nasal

vestibule of the uninjured side, and operating procedures to expose bilateral anterior wall of the maxillary sinus and apertura piriformis were not necessary<sup>[4]</sup>. We modified this operation, we made an incision on the injured side, omitted the incision on the normal side, the incision between the lateral cartilage of the nose and nasal alar cartilage. This procedure also can expose the tissues upwards on the operative side, sufficiently expose the anterior wall of the maxillary sinus, the processus frontalis maxillae, the apertura piriformis and nasal bone. The modified operation simplified operating procedures, diminished tissue damage, shortened operating time, and achieved satisfactory results.

The modified midfacial degloving operation can be applied to a maxillectomy. Compared to lateral rhinotomy, the major advantages are: *i*) There is little hemorrhage. It avoids hemorrhage from the angular artery and angiorrhagia of the dermis layer. Furthermore, incisions in the oral cavity can be made directly by an electro-tome, thus diminishing hemorrhage. The incisions heal quickly. *ii*) Tissue damage is diminished. It omits an incision between the lateral cartilage of the nose and nasal alar cartilage. If the lesion is located on one side, the incision on the normal side is diminished soon. *iii*) The field of operation is clear. It sufficiently exposes the anterior wall of the maxillary sinus, the processus frontalis maxillae, tuber maxillae, apertura piriformis and nasal bone<sup>[5]</sup>. It has been reported that, maxillectomy and exenteration of the orbit is fairly difficult through a midfacial degloving operation<sup>[6]</sup>. We concluded that extended maxillectomy and exenteration of the orbit were satisfactory through the modified midfacial degloving operation. *iv*) Facial incisions and cicatrice are avoided, thereby lightening the patients's stress. This is the most important feature of this operation. One patient had slight facial fallling because the zygomatic arch was cut in an extended maxillectomy, and had nothing to do with the method of operation. *v*) A ambi-pediced mucosa flap by the lateral mucosa of the nasal cavity is made, and the anterior border of this flap up is sewed with the nasal vestibule. Stenosis of the nasal vestibule can be prevented if the posterior extremity is not sewed up. The other incisions were closed with apposition sutures. *vi*) Different procedures for different patients are

based on the location of the tumor. If the hard palate and dental process are not involved, the mucous flap of the hard palate is retained, and it can prevent backstreaming in the nasal cavity and open rhinolalia.

In conclusion, a midfacial degloving operation or its modification can be used for a low potentially malignant tumor<sup>[7]</sup> and part of a high potentially malignant tumor<sup>[8]</sup>. Partial resection of the maxilla, total maxillectomy, even extended maxillectomy can be carried out through the modified midfacial degloving operation<sup>[9–11]</sup>. Also, a midfacial degloving operation by nasal face unification can be used to treat a tumor which cross-connects the nose and cranium<sup>[12]</sup>.

Recently, the accuracy and safety have been improved with the help of a nasal endoscopic technique<sup>[13]</sup>. It can expose and thoroughly resect a tumor, shorten operating time, lighten tissue damage, diminish hemorrhage and avoid a facial incision. This method has the advantage of being minimally invasive surgery and has merit for clinical applications<sup>[14,15]</sup>.

## References

- 1 Casson PR, Bonnanno PC, Converse JM. The midfacial degloving procedure. *Plast Reconstr Surg* 1974; 53: 102–103.
- 2 Greene FL, Page DL, Flirting ID, et al. *AJCC cancer staging handbook*. 6th ed. New York: Springer-Verlag 2002, 73–80.
- 3 Browne JD. The midfacial degloving procedure for nasal, sinus, and nasopharyngeal tumors. *Otolaryngol Clin North Am* 2001; 34: 1095–1104.
- 4 Krause GE, Jafek BW. A modification of the mid-face degloving technique. *Laryngoscope* 1999; 109: 1781–1784.
- 5 Cultrara A, JB Turk, G Har-El. Midfacial degloving approach for repair of naso-orbital-ethmoid and midfacial fractures. *Archives of facial Plastic Surgery* 2004; 6: 133–135.
- 6 Zhang HC, Zhang QQ, Yao YJ. Study of the midfacial degloving in surgery of nasal affections (with a report of 10 cases). *Er Bi Hou Xue Bao* 1994; 8: 33–34 (Chinese).
- 7 El-Banhawy OA, Shehab El-Dien AE-H, Amer T. Endoscopic-assisted midfacial degloving approach for type III juvenile angiofibroma. *Int J Pediatr Otorhinolaryngol* 2004; 68: 21–28.
- 8 Zaghoul AS, Nough MA, Fatah HA. Midfacial degloving approach for malignant maxillary tumors. *J Egypt Natl Canc Inst* 2004; 16: 69–75.
- 9 Jeon SY, Jeong JH, Kim HS, et al. Hemifacial degloving approach for medial maxillectomy: a modification of midfacial degloving approach. *Laryngoscope* 2003; 113: 754–756.
- 10 Liu YH, Zhang KL, Sha Q, et al. Study of the modified midfacial degloving in surgery of sinonasal tumors. *Er Bi Hou-Tou Jing Wai Ke* 2002; 9: 335–338 (Chinese).
- 11 Katsuhisa I, Hideaki S, Takeshi O, et al. Midfacial degloving approach facilitated by endoscope to the sinonasal malignancy. *Auris Nasus Larynx* 1998; 25: 289–293.
- 12 Lawson W, Kaufman MR, Biller HF. Treatment outcomes in the management of inverted papilloma: an analysis of 160 cases. *Laryngoscope* 2003; 113: 1548–1556.
- 13 Sun WZ, Xu ZW, Li JH, et al. Nasal endoscopic surgery by modified midface degloving approach for spongiform angioma in face: a case report. *Zhonghua Er Bi Hou Tou Jing Wai Ke* 2006; 41: 467 (Chinese).
- 14 Howard DJ, Lund VJ. The role of midfacial degloving in modern rhinological practice. *J Laryngol Otol* 1999; 113: 885–887.
- 15 Qin SH. The exploration of minimally invasion–minimally invasive surgery–minimally invasive technology. *Zhongguo Jiao Xing Wai Ke Zha Zhi* 2005; 13: 805–806 (Chinese).