Chin J Clin Oncol (2008) 5: 459~461
DOI 10.1007/s11805-008-0459-7

Diaphyseal Chondroblastoma in the Tibia: One Case Report and Literatures Review

Xiaojun Ma
Yang Dong
Chunlin Zhang
Bingfang Zeng
Jian Ding

Department of Orthopedics, Shanghai 6th People's Hospital of Shanghai Jiao Tong University, Shanghai 200233, China.

Correspondence to: Yang Dong
Tel: 86-21-6436 9181 ext. 8081
E-mail: dongyang_520@yahoo.com.cn

Received July 11, 2008; accepted September 9, 2008.

CJCO http://www.cjco.cn
E-mail: 2008cocr@gmail.com
Tel (Fax): 86-22-2352 2919

KEY WORDS: bone tumor, chondroblastoma (CB), diaphysis of tibia, unusual locations.

Introduction

Chondroblastoma is a rare benign cartilaginous neoplasm that accounts for approximately 1% of all bone tumors and characteristically arises in the epiphysis of a long bone, particularly the humerus, femur and tibia[1]. Chondroblastoma can affect people of all ages. However, it is most common in children and young adults between the age of 10 and 20 years. Occasionally it can be followed by a more aggressive course invading the joint spaces, adjacent bones and rarely resulting in metastases. It is defined as a lytic bone lesion with a predilection for the epiphyseal region of long bones in skeletally immature individuals, although 50% of the tumors also involve the metaphysis. However, purely metaphyseal and diaphyseal tumors are exceedingly rare. In fact, the only diaphyseal chondroblastoma we found in the literature was located in a metacarpal bone[2,3] and the distal femor[4]. We describe a Chondroblastoma arising from the diaphysis of the tibia, which, to the best of our knowledge, is the first diaphyseal chondroblastoma of the tibia reported in the world literature.

Case Report

An 18-year-old male referred to the Shanghai 6th People's Hospital of Shanghai Jiao Tong University and complained of a 6-month pain history of the middle region of his left leg. Pain was insidious in onset. It gradually worsened and caused difficulty in walking for approximately 2 months. Anteroposterior and lateral X-rays before operation demonstrated an eccentric osteolytic lesion with a sclerotic margin in the diaphysis of the left tibia (Fig.1A). Axial CT scan showed cartilaginous matrix and a lytic lesion in the middle of the tibia (Fig.1B). Magnetic resonance imaging revealed a lesion within the left tibia diaphysis with intermediate signal intensity and focal central low signal areas on T1-weighted images; T2-weighted images showed mainly middle-signal areas (Fig.2). Physical examination was remarkable with pain upon palpation of the middle anterior left leg and soft tissue swelling, although no discrete mass was palpable. Strength, sensation, and pulse were all normal. The tests of alkaline phosphatase are 139 U/L, Phosphate Concentration is 1.67 mmol/L. The results of other laboratory examinations were normal. The patient was scheduled for curettage with autogenous iliac bone grafts. After decalcification an aggregate of red-tan soft tissue was routinely

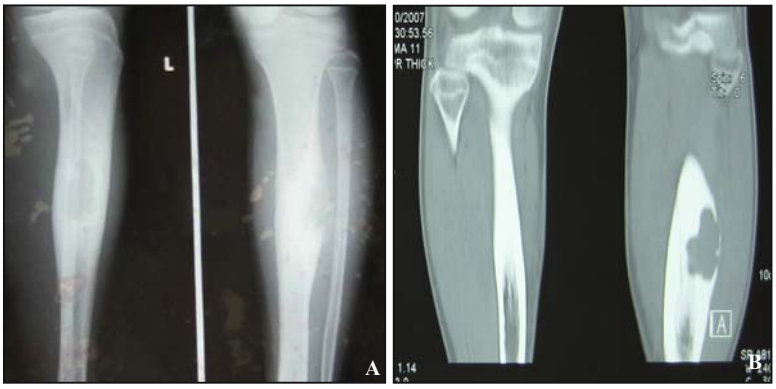

Fig.1. A, X-ray before the operation; B, Axial CT before the operation. Conventional radiographs and CT showed a lytic lucent area within the left tibia. No fractures or dislocation of the tibia was noted.

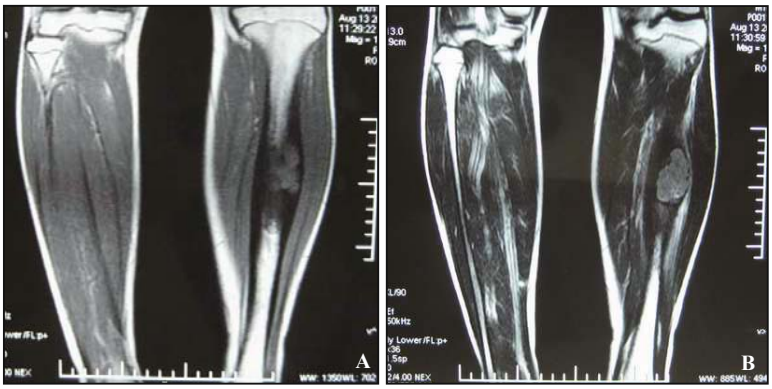

Fig.2. A, T1-weighted images; B, T2-weighted images. MRI before the operation showed cystic areas with a heterogeneous lesion in the left tibia. Mild expansion of the bone was noted. However pathologic fracture was not seen.

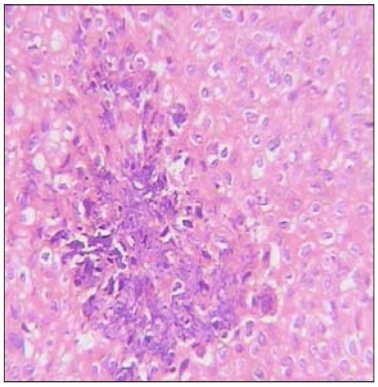

Fig.3. High-power photomicrograph of the chondroblastoma shows a fine calcification around the chondroblasts, scattered multinucleated giant cells ("chicken-wire" calcification; H&E stain, ×200).

Table 1. Metaphyseal and diaphyseal chondroblastomas

		Patient's information		
Time	Author	Age	Sex	Location
1972	Dahlin DC [14]	13	F	Distal metaphysic and shaft of femur
1976	Schwinn CP [15]	14	M	Metadiaphysis of radius
1985	Bloem JL [16]	25	F	Metadiaphysis
1986	Sotelo-Avila [17]	11	F	Proximal metaphysis and diaphysis of femur
1986	Ippolito E [2]	15	M	Disphysis of the first metacarpal
2000	Peh WCG [19]	13	M	Metadiaphysis of the proximal phalanx of the thumb
2005	D Azorion [4]	13	F	Distal femoral diaphysis
2006	D Adam T [20]	17	M	Distal femoral diaphysis
2008	MA Xiaojun	18	M	Middle tibia of diaphysis

processed to hematoxylin and eosin (H&E stain) glass slides. With paraffin immunohistochemistry for S-100 testing positive, the pathology supported the final diagnosis as chondroblastoma (Fig.3). The patient reported no problems at his follow up appointment five months later and his radiographs showed evidence of normal bony healing.

Discussion

According to the WHO 2002 definition, "chondroblastoma is a benign, cartilage-producing neoplasm usually arising in the epiphyses of skeletally immature patients." It accounts for less than 1% of all bone tumors. This tumor was originally described by Kolodny[1] in 1927 as a ''cartilage containing giant cell tumor'', and later as a ''calcifying giant cell tumor'' by Ewing[5] in 1928[6]. He recognized the benign nature of the lesion and that it was often mistaken for a malignant tumor of the bone. Codman[7], in 1931 gave the first detailed description of this tumor. He reported 9 cases in which tumors occurred in the upper end of the humerus. In 1942 Jaffe and Lichtenstein introduced the term ''benign Chondroblastoma of bone'' and rejected the concept that this neoplasm was of giant cell origin. They proposed that this tumor was derived from cells ''best interpretable as cartilage germ cells''. In a review of five large series, Mayo-Smith et al. [8] reported that the distal femur and proximal tibia are the most common sites overall (18% each), followed by the proximal humerus (17%), proximal femur (16%), and the foot (12%). Mostly, authors describe CB as an eccentric, oval or round well-defined lesion and with a predilection for the epiphyseal region of the long bones, mainly in the proximal femur, proximal tibia, and proximal humerus. Other non long bone areas have been reported, such as the acetabular region of the pelvis, scapula, spine, ribs, patella, and occasionally the craniofacial bones. Our pubmed search has found that the contiguous involvement of the common region occurs frequently, but purely diaphyseal tumors are extremely rare. Even we have research several case reports of chondroblastoma presenting in some unusual locations, including the external ear [9] skin [10] diaphysis of femur[4], rib[11], metacarpal[3], maxilla[12] and subcutaneous

tissues[13]. Indeed, there are only two cases of diaphyseal CB reported in the diaphysis, but both cases happen in the distal femur (Table 1).

Histologically, chondroblastoma is a highly cellular tumor consisting of uniform, round to polygonal cells with well-defined cytoplasmic borders, slightly eosinophilic cytoplasm, and a round nucleus (chondroblast). They are packed in a pseudolobulated pattern in a chondroid matrix. Characteristically, a fine network of pericellular calcification ("chicken wire") is found. Osteoclast-like giant cells are almost always present. The lesion's epiphyseal location is an important diagnostic radiological feature. Our case demonstrated the typical features of chondroblastoma, particularly the presence of chicken wire calcifications surrounding chondroblasts. To the best of our knowledge, the present case is the first purely diaphyseal chondroblastoma arising in the tibia. Several studies on the origin of chondroblastoma have concluded that it is derived from epiphyseal cartilage cells. A study on cartilage growth plate signaling molecules concluded that chondroblastoma is a neoplasm originating from a mesenchymal cell committed toward chondrogenesis via active growth plate signaling pathways [19].This would explain the close relationship between the growth plate cartilage and the epimetaphyseal location of the chondroblastoma. However, in the present case we described a chondroblastoma remote from the physeal cartilage. A reasonable explanation for this unusual location was offered by Brien et al.[20] who reported that chondroblastoma is derived from a multipotential mesenchymal cell of the tendon sheath that, and within an osseous environment, would have a tendency to chondroid formation. Perhaps the origin of the lesion in our patient was from an embryonic rest of the primitive cartilage prior to its endochondral ossification. However, we believe that further studies will be necessary to explain the diaphyseal origin of this chondroblastoma. In summary, this is the first reported case of chondroblastoma in the diaphysis of the tibia.

References

1 Kurt AM, Unni KK, Sim FH, McLeod RA. Chondroblastoma of bone. Hum Pathol 1989; 20: 965-976.
2 Ippolito E, Tudisco C, Mariani PP. Rare forms of chondroblastoma. Cystic and diaphyseal types. Ital J Orthop Traumatol 1986; 12: 455-460.
3 Bliss DG, Mann RJ. Chondroblastoma of a Metacarpal Report of a Case and Review of the Literature .Clinlcal otthopaedis and Related Reaearch 1985; 194: 211-213.
4 D. Azorín I, González-Mediero I,Colmenero I. Diaphyseal chondroblastoma in a long bone: first report. Skeletal Radiol 2006; 35: 49-52.
5 Kolodny A. Bone sarcoma: the primary malignant tumor of bone and the giant cell tumor. Surg Gynecol Obstet Y 1927; 44: 211-214.
6 Ewing J, Neoplastic Diseases. A Treatise on Tumors, 3rd ed. Philadelphia: W.B. Saunders Co.; 1928.
7 Codman EA. Epiphyseal chondromatous giant cell tumors of the upper end of the humerus. Surg Gynecol Obstet 1931; 52: 543-548.
8 Mayo-Smith W, Rosenberg AE, Khurana JS, et al. Chondroblastoma of the rib. A case report and review of the literature. Clin Orthop 1990; 251: 230-234.
9 Kingsley TC, Markel SF. Extraskeletal chondroblastoma. Cancer 1971; 271: 203-205.
10 Weinrauch L, Katz M, Pizov G. Primary benign chondroblastoma cutis: extraskeletal manifestation without bone involvement. Arch Dermatol 1987; 123: 24-25.
11 Mayo-Smith W, Rosenberg AE, Khurana JS .Chondroblastoma of the rib. A case report and review of the literature. Clinical Orthopeadics and Related Research 1990; 251: 230-234.
12 Rastogi Madhup, M Srivastava, AN Srivastava. Chondroblastoma of maxilla. Oral Oncology Extra 2005; 41: 159-161.
13 Abdul-Karim FW, Ayala AG, Spjut HJ. Case report 321 (Extraosseous chondroblastoma in the subcutaneous tissues of the right shoulder). Skelet Radiol 1985; 14: 73-75.
14 Dahlin DC, Ivins JC et al. Chondroblastoma, A study of 125 cases. Benign Cancer 1972; 30: 401-413.
15 Ackerman LV, Spjut HJ, Abell MR, et al. Differential diagnosis of giant cell lesions of bone. Bones and Joints 1976; 226-229.
16 Bloem JL, Mulder JD. Chondroblastoma: a clinical and radiological study of 104 cases. Skeletal Radiol 1985; 14: 1-9.
17 Sotelo-Avila C, Sundaram M, Kyriakos M, et al. Case report 373: diametaphyseal chondroblastoma of the upper portion of the left femur. Skeletal Radiol 1986; 15: 387-390.
18 Peh WCG, Shek TWH, Ip WY. Metadiaphyseal chondroblastoma of the thumb. Skeletal Radiol 2000; 29: 176-180.
19 Romeo S, Bovée JVMG, Jadnanansing NAA, et al. Expression of cartilage growth plate signalling molecules in chondroblastoma. J Pathol 2004; 202: 113-120.
20 Brien EW, Mirra JM, Ippolito V. Chondroblastoma arising from a non epiphyseal site. Skeletal Radiol 1995; l24: 220-222.