

# Correlation of VEGF and COX-2 Expression with VM in Malignant Melanomas

Baocun Sun<sup>1</sup>

Shiwu Zhang<sup>1</sup>

Xiulan Zhao<sup>2</sup>

Yanxue Liu<sup>1</sup>

Chunsheng Ni<sup>1</sup>

Danfang Zhang<sup>1</sup>

Hong Qi<sup>1</sup>

Zhiyong Liu<sup>1</sup>

Xishan Hao<sup>1</sup>

<sup>1</sup> Department of Pathology, Tianjin Cancer Institute and Cancer Hospital, Tianjin 300060, China.

<sup>2</sup> Department of Pathology, Tianjin Medical University, Tianjin 300070, China.

**OBJECTIVE** To investigate the relationship between vascular epithelial growth factor (VEGF) and cyclooxygenase-2 (COX-2) in melanomas and the expressive difference of VEGF and COX-2 between melanomas with and without vasculogenic mimicry (VM).

**METHODS** Sixty cases of malignant melanomas embedded in paraffin were studied. The tumors were divided into a high-grade malignant group and a low-grade malignant group based on their tumor type, atypia and survival time of the patient. Then tissue microarrays were produced from these paraffin-embedded tumor tissues which were stained for VEGF, COX-2 and PAS. The difference in expression between VEGF and COX-2 in the malignant melanomas was compared using a grid-count. In addition, the tumors were also divided into mimicry and non-mimicry groups based on their PAS staining. Then the differences between the PAS positive and negative areas of the 2 groups were compared.

**RESULTS** In malignant melanomas with VM, VEGF and COX-2 expression was less in tumors in which VM was absent, but VEGF, COX-2 expression in high-grade malignant melanomas was higher than that in low-grade malignant melanomas. Expression of VEGF was correlated with COX-2 expression.

**CONCLUSION** VM exists in some high-grade malignant melanomas. The differences and relations between VEGF and COX-2 showed that some high-grade malignant melanomas possess a unique molecular-mechanism of tumor metastasis and blood supply.

**KEYWORDS:** VEGF, VM, cyclooxygenase-2, tissue microarray.

**V**M was first described by Maniotis et al. in 1999<sup>[1,2]</sup> as a system of unique vascular channels through which tumors acquire a blood supply for growth and metastasis. VM is different from tumor angiogenesis and is formed by a dissimilar molecular mechanism.<sup>[3-7]</sup> Research regarding VM has been steadily increasing. Results from our study, which involved 60 cases of malignant melanomas stained for VEGF, COX-2 and PAS, showed that there was a statistically significant correlation between VEGF and COX-2 in these cancers. Expression of VEGF and COX-2 was also related to the malignant grade of melanomas. The degree of expression of VEGF and COX-2 in malignant melanomas with VM was less than that found in malignant melanomas in which VM was absent.

Received February 6, 2004; accepted August 31, 2004.

## MATERIALS AND METHODS

### Tissue specimens

Sixty specimens of malignant melanomas from the Tianjin Cancer Hospital were selected for this study. The specimens chosen were from patients who had died of malignant melanoma and whose diagnosis had been carefully verified. The tumors used to make tissue microarrays were divided into a high-grade malignant group and a low-grade malignant group based on the tumor type, atypia and survival time of the patient.

The melanomas which had been embedded in paraffin were re-examined and sectioned again. Four features recorded for each sample included: well-differentiated, de-differentiated, site of interaction with normal tissue and the site of VM. Sections on silica glass slides were used in this study.

### Immunohistochemical methods

VEGF and COX-2 immunohistochemically staining was performed with a common 2-way technique. Briefly, tissues used for the microarray sections were deparaffinized in xylene and rehydrated in a series of ethanol solutions (100-75%). The endogenous peroxidase activity was blocked by incubation in a 3% methanolic hydrogen peroxide solution for 10 min. The sections were then microwaved in 20 mM citric acid solution for 12 min to retrieve antigens followed by preincubation with 10% non-immune serum to block the non-specific binding with the second antibody. Subsequently the tissue microarray sections were incubated at 4°C overnight with mouse anti-VEGF and COX-2 antibodies (Sigma Chemical, St. Louis, Mo., USA). After being washed 3 times for 6 min, the sections were incubated with common IgG-HRP at 37°C for 10 min. This was followed by DAB staining. The sections were then rinsed with distilled water for 5 min and incubated with periodic acid-Schiff (PAS) for 15 min. Finally, all of the sections were counterstained with hematoxylin.

### Counting methods

After double staining, counting was conducted using

an OLMPUS CH-2 microscope with 16 × 16 D gridding magnified 400×. A total of 256 total cross points of the intersecting(Pt) gridding were examined. A cross point was counted just when CD31 and PAS positive areas covered the cross point, whereas the cross point would not be counted when CD31 and PAS positive areas laid outside of the cross points. CD31 and PAS counting must be conducted in the same microscopic field. In the same tumor, Pc (positive counting points) of CD31 and PAS must be equally counted. Each side of the micro square (d) is the same and the test area is  $A_t = P_c \times d^2$ .

### Statistical methods

A SPSS for Windows 10.0 statistical software package was used to conduct the ranks sum test and produce correlations. A difference with  $P < 0.05$  was considered significant.

## RESULTS

### The difference of VEGF expression between highly malignant and lowly malignant melanomas and the correlation of VEGF with VM

The results of VEGF immunohistochemical detection showed that the VEGF antigen expressed in the tumor cytoplasm around the nuclei (Fig.1) and the degree of expression varied with the malignancy of the melanomas. Statistical analysis showed that the positive area of VEGF expression in highly malignant melanomas was somewhat greater than that found in lowly malignant melanomas. However, there was no significant difference between them because of the small number (Table 1). On the other hand, the VEGF expression in some highly malignant melanomas with VM was lower than in malignant melanomas without VM. The difference between them was statistically significant ( $P=0.000$ , Table 2).

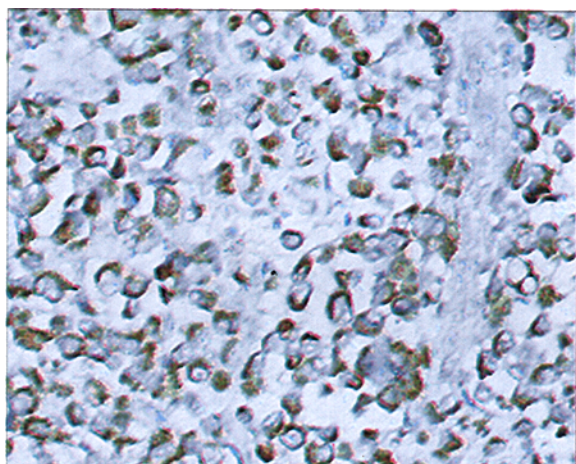
Furthermore, the grid-counting results indicated that the degree of expression of VEGF and COX-2 was correlated ( $r=0.568$ ,  $P=0.000$ ). Morphologic observation showed that not only were the positive areas between VEGF and COX-2 identical but the positive degrees of expression were identical.

**Table 1. Comparison of VEGF expression between highly malignant melanomas and lowly malignant melanomas**

Group	n	$\bar{x} \pm SD$	t	P
High malignancy	30	180.3± 67.7	1.666	0.101
Low malignancy	30	149.7± 74.2		

**Table 2. Comparison of VEGF expression between highly malignant melanomas with or without VM.**

Group	n	$\bar{x} \pm SD$	t	P
VM	8	51.0± 49.6	4.048	0.000
No VM	52	182.6± 57.8		



**Fig.1.** Immunohistochemical staining for VEGF in malignant melanomas × 200.

**The COX-2 expression between highly malignant and lowly malignant melanomas**

The immunohistochemical detection of the COX-2 antigen showed that it was located in the tumor cytoplasm(Fig.2).

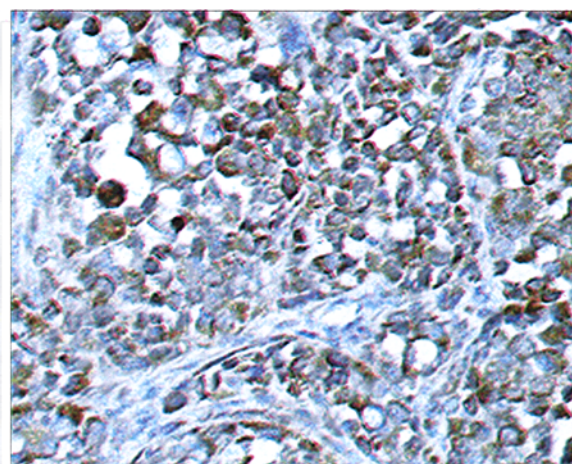
The grid-counting results indicated that COX-2 expression in highly malignant melanomas was higher than in lowly malignant melanomas ( $P=0.003$ ) but COX-2 expression in malignant melanomas with VM was lower than in malignant melanomas without VM. The difference showed statistical significance (Table 3, 4).

**Table 3. Comparison of COX-2 expression between highly malignant and lowly malignant melanomas**

Group	n	$\bar{x} \pm SD$	t	P
High malignancy	30	188.6± 59.2	3.141	0.003
Low malignancy	30	132.5± 77.9		

**Table 4. Comparison of COX-2 expression between high-grade malignant melanomas with VM and malignant melanomas without VM**

Group	n	$\bar{x} \pm SD$	t	P
VM	8	80.0± 86.7	2.795	0.005
No VM	52	172.9± 64.5		



**Fig.2.** Immunohistochemical stains for COX-2 in malignant melanomas × 200.

**DISCUSSION**

**COX-2 expression in malignant melanomas**

Cyclooxygenase (COX) is the key enzyme in the conversion of arachidonic into 20-carbon prostaglandins.<sup>[8,9]</sup> Cyclooxygenase is comprised of 2 isoenzymes, COX-1 and COX-2. COX-1 takes part in the synthesis of physiological prostaglandins while COX-2 participates in the synthesis of pathological prostaglandins.<sup>[10-13]</sup> The pathological prostaglandins produced may play a role in the regulation of many tumor biological behaviors, including tumor angiogenesis, survival time and the reaction to

treatment. Not only do inflammatory cells such as granulocytes and macrophages contain COX-2, but the enzyme is found in some tumor cells too. COX-2 is an inducible enzyme and can be activated by many biological factors, such as transforming growth factor- $\alpha$  (TGF- $\alpha$ ), endothelial cell growth factor receptor, endotoxin and cytokines such as IL and TNF.<sup>[14,15]</sup> These inducible factors may come from the blood and may increase along with the expansion of the vasculature.

It has been reported that inducible COX-2 has several biologic effects, such as enhancement of tumor cell proliferation, inhibition of apoptosis, stimulation of angiogenesis, and inhibition of immunosurveillance.<sup>[16-18]</sup> Our study demonstrated that the positive expression of COX-2 varied with malignancy of the tumors. The expression of COX-2 in highly malignant melanomas was higher than that in lowly malignant melanomas. This result suggests that COX-2 plays an important role in the procession of tumor-cell progress. There were many vessels in highly malignant melanomas in which VM was present. Tumor tissues are supplied with adequate oxygen, nutrients as well as other chemical and biological substance through VM and blood vessels. These chemical and biological substances can cause induction of COX-2, resulting in its enhanced expression in high-grade malignant melanomas, especially in areas located in the tumor tissue periphery. This suggest that COX-2 expression is regulated by interaction of mesenchymal cells with tumor cells. COX-2 produced by tumor cells in progression of the tumor can be suppressed by COX-2 inhibitors which can restrain tumor cellss metastasis by inhibiting the synthesis of MMP-2 and PgE<sub>2</sub>.<sup>[19]</sup> A special COX-2 inhibitor-NS 398 which suppressed the synthesis of PgE<sub>2</sub> in malignant melanomas can inhibit the synthesis of COX-2.<sup>[20]</sup> COX-2 inhibitors can influence the COX-2 level of tumor cells and decrease tumor cell invasion and metastasis.<sup>[21]</sup>

#### **VM and VEGF expression in malignant melanomas**

VEGF is an alkaline protein. Only tumor cells can secrete VEGF antigens and its receptor is located on the

surface of endothelial cells. Anoxia is an important condition which can induce the production of VEGF.<sup>[22,23]</sup> The degree of VEGF expression in highly malignant melanomas tended to be more than in low-grade malignant melanomas. Because of the rapid growth in highly malignant melanomas, the blood supply must be enhanced to satisfy the needs of the tumor cells. There are 2 means for the cells to acquire a blood supply. One is angiogenesis, the other is VM. At an early growth stage, tumor cells proliferate quickly and the blood supply from angiogenesis is not adequate to satisfy this demand. Under these circumstances, VM is produced by tumor cells through self-transformation and reformation of the matrix-model. Although VEGF expression tended to be greater in highly malignant melanomas than in lowly malignant melanomas, its expression in melanomas with VM was lower than that in melanomas without VM.

#### **VM and immunohistochemical detection for VEGF and COX-2**

It has been reported that the PgE<sub>2</sub> level increases with COX-2 activity in tumor cells and that the degree of VEGF expression increases with PgE<sub>2</sub> levels.<sup>[24]</sup> Prostaglandins play a critical role in the progression of tumor cells by regulating tumor angiogenesis.<sup>[25]</sup> Results from this studies showed that a high level of COX-2 and subsequent PgE<sub>2</sub> in tumor tissues indicated a high degree of malignancy. The level of COX-2 influenced the prostaglandin level and VEGF expression. The level of VEGF was related to angiogenesis which can induce tumor cell invasion and metastasis.<sup>[26]</sup> At the same time VEGF can inversely influence COX-2 expression by changing the flux of blood into the tumor.

Our studies indicated that both COX-2 and VEGF expression in highly malignant melanomas with VM was lower than in melanomas without VM. VEGF expression is closely linked to COX-2 expression. The reason may be related to VM. Studies from Feleszko et al.<sup>[19]</sup> concluded that the level of PgE<sub>2</sub> varied remarkably among different melanoma cell lines carried in mice, but the exact reason was unknown.

Perhaps VM exists in some melanoma cell lines carried in vivo. Because of VM, COX-2 inhibitors maybe useful for treatment of some patients bearing malignant melanoma. Studies from Tamura et al.<sup>[11]</sup> indicated that VEGF affected COX-2 expression and PGE<sub>2</sub> synthesis. Fujiwaki et al. also reported that COX-2 expression was associated with high micro-vessel density.<sup>[12,27]</sup> Thus, we conclude that when VM in a tumor exists, VEGF expression may be a related to COX-2 expression. Tumor cells require a plentiful supply of blood, oxygen and nutrition. This requirement may induce down-regulation of VEGF expression in tumor cells. Down-regulation of VEGF expression is consistent with a fall in COX-2 expression.<sup>[28]</sup>

It has been reported that appropriate doses of aspirin can affect the activity of COX-2 in the metabolic pathway that forms PGE.<sup>[16]</sup> Animal experiments also have shown that a platelet-activated factor, such as chuanxiong, a type of Chinese traditional medicine, and cyclooxygenase inhibitors, such as indomethacin can protect endothelial cells from damage. It has been documented that VEGF secreted by tumor cells binds to receptors located on the surface of endothelial and other tissue cells which have VEGF receptors. In the procession of malignant melanoma cells that form metastatic foci, the tumor cells must pass through the walls of vessel lined with endothelial cells. So as infiltrative ability increases, the metastatic capacity becomes greater. The expression of COX-2, which plays an important role in the progression of tumor invasion and metastasis, was higher in highly malignant melanomas than in lowly malignant melanomas. A high level of COX-2 activity can damage endothelial cells and induce tumor cells metastasis. It is possible that COX-2 inhibitors can inhibit tumor cell metastasis by protecting endothelial cells from damage.

## REFERENCES

- 1 Maniotis AJ, Folberg R, Hess A, et al. Vascular channel formation by human melanomas cells in vivo and vitro : VM. *Am J Pathol.* 1999; 3:739-752.
- 2 Sharma N, Seftor RE, Seftor EA, et al. Prostatic tumor cell plasticity involves cooperative interactions of distinct phenotypic subpopulations: role in VM. *Prostate.* 2002; 3: 189-201.
- 3 Folberg R, Hendrix MJ, Maniotis AJ. VM and tumor angiogenesis. *Am J Pathol.* 2000; 2:361-381.
- 4 Hendrix MJ, Seftor EA, Kirschmann DA, et al. Molecular biology of breast cancer metastasis. Molecular expression of vascular markers by aggressive breast cancer cells. *Breast Cancer Res.* 2000; 6:417-422.
- 5 Hao XS, Sun BC, Zhang SW, et al. Microarray study of VM in bi-directional differentiation malignant tumor. *Chin J Med.* 2002; 10:1298-1302.
- 6 Sun BC, Zhang SW, Zhao XL, et al. Study on VM in malignant melanomas. *Chin J Path.* 2003; 6:539-543.
- 7 Hao XS, Sun BC, Zhang SW, et al. Correlation between the collagen IV, VEGF and VM. *Chin J Oncol.* 2003; 6:524-526.
- 8 Denkert C, Kobel M, Berger S, et al. Expression of cyclooxygenase-2 in human malignant melanomas. *Cancer Res.* 2001; 1:303-308.
- 9 Gallo O, Masini E, Bianchi B, et al. Prognostic significance of cyclooxygenase-2 and angiogenesis in head and neck squamous cell carcinoma. *Hum Pathol.* 2002; 7:708-714.
- 10 Cahlin C, Gelin J, Delbro D, et al. Effect of cyclooxygenase and nitric oxide synthase inhibitors on tumor growth in mouse tumor models with and without cancer cachexia related to prostanoids. *Cancer Res.* 2000; 6:1742-1749.
- 11 Tamura M, Sebastian S, Gurates B, et al. Vascular endothelial growth factor up-regulates cyclooxygenase-2 expression in human endothelial cells. *J Clin Endocrinol Metab.* 2002; 7:3504-3507.
- 12 Fujiwaki R, Iida K, kanasaki H, et al. Cyclooxygenase-2 expression in endometrial cancer: correlation with microvessel count and expression of vascular endothelial growth factor and thymidine phosphorylase. *Hum Pathol.* 2002; 2:213-219.
- 13 Karabe A, Shimada Y, Uchida S, et al. Expression of cyclooxygenase -2 in primary and remant gastric carcinoma. *J Surg Oncol.* 2002; 2:79-88.
- 14 Sunayama K, Konno H, Nakamura T, et al. The role of cyclooxygenase in two different morphological stages of intestinal polyps in APC (Delta 474) knockout mice. *Carcinogenesis.* 2002; 8:1351-1359.
- 15 Seno H, Oshima M, Ishikawa TO, et al. Cyclooxygenase-2 and prostaglandin E (2)-dependent angiogenesis in APC (Delta 716) mouse intestinal polyps. *Cancer Res.* 2002; 2: 506-511.
- 16 Sales KJ, Katz AA, Howard B, et al. Cyclooxygenase-1 is up-regulated in cervical carcinomas: autocrine / paracrine regulation of cyclooxygenase -2, prostaglandin receptors,

- and angiogenic factors by cyclooxygenase-1. *Cancer Res.* 2002; 2:424-432.
- 17 Shiota G, Okubo M, Noumi T, et al. Cyclooxygenase-2 expression hepatocellular carcinoma. *Hepatogastroenterology.* 1999; 25:407.
  - 18 Koga H, Sakisaka S, Ohishi M, et al. Expression of COX-2 in human hepatocellular carcinoma: relevance to tumor dedifferentiation. *Hepatology.* 1999; 3:688.
  - 19 Feleszko W, Jalili A, Olszewska D, et al. Synergistic interaction between highly specific cyclooxygenase -2 inhibitor, MF-tricyclic and lovastatin in murine colorectal cancer cell lines. *Oncol Rep.* 2002; 4:879-885.
  - 20 Takahashi S, Fujita T, Yamamoto A. Role of cyclooxygenase-2 in helicobacter pylori-induced gastritis in Mongolian gerbils. *Am J Physiol Gastrointest Liver Physiol.* 2000; 4:791-798.
  - 21 Dixon DA, Tolley ND, King PH, et al. Altered expression of the mRNA stability factor HuR promotes cyclooxygenase-2 expression in colon cancer cells. *J Clin Invest.* 2001; 11:1657-1665.
  - 22 Holash J, Maisonpierre PC, Compton D, et al. Vessel cooption, regression and growth in tumors mediated by angiopoietins and VEGF. *Science.* 1999; 284:1994-1998.
  - 23 O'Byne KJ, Koukourakis MI, Giatromanolaki A, et al. Vascular endothelial growth factor, platelet-derived endothelial cell growth factor and angiogenesis in non-small-cell lung carcinoma. *Br J Cancer.* 2000; 8:1427-1432.
  - 24 Cianchi F, Cortesini C, Bechi P, et al. Up-regulation of cyclooxygenase-2 gene expression correlates with tumor angiogenesis in human colorectal cancer. *Gastroenterology.* 2001; 6:1339-1347.
  - 25 Fosslien E. Review: molecular pathology of cyclooxygenase-2 in cancer-induced angiogenesis. *Ann Clin Lab Sci.* 2001; 4:325-348.
  - 26 Jaeckel EC, Raja S, Tan J, et al. Correlation of expression of cyclooxygenase-2, vascular endothelial growth factor, and peroxisome proliferator-activated receptor delta with head and neck squamous cell carcinoma. *Arch Otolaryngol Head Neck Surg.* 2001; 10:1253-1259.
  - 27 Kara M, Wada T, Akatsuka T, et al. Vascular endothelial growth factor expression in untreated osteosarcoma is predictive of pulmonary metastasis and poor prognosis. *Clin Cancer Res.* 2000; 2:572-577.
  - 28 Van Rompaey L, Holland E, Grosveld G. TEL Induces Aggregation in Transformed Cells and Induces Tube Formation in NIH3T3-UCLA Cells. *Biochem Biophys Res Commun.* 2002; 4:820-828.