



ORIGINAL ARTICLE

Prediction of cervical lymph node metastases in papillary thyroid microcarcinoma by sonographic features of the primary site

Xi Wei^{1*}, Meng Wang^{2*}, Xiaoqing Wang¹, Xiangqian Zheng², Ying Li³, Yi Pan⁴, Yueguo Li⁵, Jiali Mu¹, Yang Yu², Dapeng Li², Ming Gao², Sheng Zhang¹

¹Department of Diagnostic and Therapeutic Ultrasonography; ²Department of Thyroid and Cervical Tumor; ³The Third Department of Breast Cancer; ⁴Department of Pathology; ⁵Department of Clinical Laboratory, Tianjin Medical University Cancer Institute and Hospital, National Clinical Research Center for Cancer, Key Laboratory of Cancer Prevention and Therapy, Tianjin, Tianjin's Clinical Research Center for Cancer, Tianjin 300060, China

ABSTRACT

Objective: To study the sonographic features of the primary site of papillary thyroid microcarcinoma (PTMC) for the prediction of cervical lymph node metastasis during preoperative diagnosis.

Methods: A total of 710 PTMC patients between 2013 and 2016 with a diagnosis of cervical lymph node metastases were reviewed. We analyzed the sonographic features of the PTMC primary site to predict ipsilateral or central lymph node metastases in univariate and multivariate models. The ratio of abutment/perimeter of the PTMC primary site was utilized to evaluate cervical lymph node status.

Results: Regarding clinical characteristics, multifocality and extrathyroidal extension were associated with cervical lymph node involvement. In the multivariate regression model, calcification and the abutment/perimeter ratio of lesions were evaluated as independent factors in level VI, ipsilateral or skip cervical lymph node metastases. The cut-off value of the ratio of abutment/perimeter of the PTMC primary site (25%) was significantly correlated with cervical lymph node metastases ($P = 0.000$).

Conclusions: Independent sonographic features, including lesion size, lesion location, calcification, and the ratio of abutment/perimeter of the primary site, were associated with cervical lymph node metastases in PTMC patients.

KEYWORDS

Ultrasonography; thyroid; lymph nodes; metastasis; evaluation

Introduction

Papillary thyroid microcarcinoma (PTMC) was defined as small thyroid tumors with a size ≤ 1 cm as the greatest diameter¹. Most clinical or occult papillary thyroid microcarcinomas are nonpalpable but can be detected by neck ultrasonography, computerized tomography (CT) or other imaging modalities²⁻³. Although papillary thyroid microcarcinoma presents indolent clinical behaviors, the local recurrent rate of PTMC was reported to be as high as 12%, with lymph node metastasis being one of the most important risk factors⁴⁻⁶. Thus, cervical lymph node metastases should be taken into account to assess the risk of

relapse in patients with PTMC. Although active surveillance is an essential strategy in PTMC⁷⁻⁹, its drawback is that if patients want to accept it, they need to have no potential of cervical lymph node metastases before enrollment⁹. To date, surgery is the initial and standard treatment for PTMC with lymph node metastases. Therefore, the option for PTMC operation or active surveillance depends on the status of cervical lymph node metastases, which indicates that preoperative assessment is critical for PTMC patients.

Clinical examination and imaging modalities are considered effective tools to predict lymph node metastases in PTMC¹. However, preoperative ultrasound (US) and CT imaging procedures have been reported to have relatively low sensitivity (20%–40%) for the detection of lymph node metastases in PTMC¹⁰ because US and CT images cannot clearly present neoplastic diseases or inflammation of cervical lymph nodes. Due to this possible confusion, clinicians must accelerate the diagnostic sensitivity in the preoperative assessment of cervical lymph node involvement in PTMC

*These authors contributed equally to this work.

Correspondence to: Xi Wei and Sheng Zhang

E-mail: weixi@tmu.edu.cn and zs19620112@126.com

Received August 31, 2018; accepted December 21, 2018.

Available at www.cancerbiomed.org

Copyright © 2019 by Cancer Biology & Medicine

patients¹¹. This retrospective study aims to explore the clinical and US features of the primary PTMC site to identify metastatic central or lateral cervical lymph nodes to enrich PTMC treatment options.

Materials and methods

Subjects

In this retrospective study, a total of 710 PTMC patients (475 females and 235 males) were identified by pathological examination and enrolled from October 2013 to September 2016. The ages ranged from 7 to 80 years old (the average age was 44 years old). All patients were submitted to cervical lymph node dissection. Of the 710 PTMC patients, 401 underwent total thyroidectomy, while the other 309 underwent thyroidectomy. A total of 486 patients underwent cervical level VI lymph node dissection, with prophylactic level VI dissection in 400 patients and therapeutic dissection in 86 cases. Therapeutic dissection of ipsilateral lymph nodes was performed in 297 patients. The retrospective study was approved by the Ethics Committee of Tianjin Medical University Cancer Institute and Hospital.

Inclusion criteria

The patients enrolled in this retrospective and consecutive study were selected on the basis of the following criteria. (1) All patients in our series underwent neck ultrasound examination for the evaluation of primary sites and cervical lymph nodes status before operation. (2) Ultrasound-guided fine needle aspiration (FNA) was performed for diagnostic purposes before the operation. Definitive diagnostic cytological findings of thyroid malignancy were determined at initial or follow-up ultrasound-guided FNA. (3) The diagnosis of primary site or cervical lymph node metastases of PTMC was pathologically confirmed after the operation (reviewed by Dr. Pan Y, who has 15 years of experience in thyroid cancer pathological diagnosis).

Ultrasound examination

Using a Phillips iU22 color Doppler ultrasonic diagnostic apparatus (Philips Medical Systems, Bothell, Washington), the 710 patients were scanned in the supine position with shoulder pillows and their necks fully exposed; along with longitudinal and transverse scans, routine examination of the bilateral thyroid lobe, isthmus and bilateral cervical lymph nodes was performed (reviewed by Dr. Wei X and Dr. Zhang S, with 10 and 25 years of experience in thyroid cancer US

diagnosis, respectively). The final diagnosis of metastatic LN involvement was made by a pathologist who had 15 years of experience in histological diagnosis of cervical LNs (reviewed by Dr. Pan Y).

Ultrasound features of thyroid lesions

The size, internal echogenicity, shape, and location of the nodule, number of nodules affected, peripheral vascularity, margin, calcification, and abutment of the thyroid capsule were all preoperatively assessed using cervical ultrasonography.

The ratio of capsular abutment over the lesion perimeter was calculated by sonography using Image pro plus (IPP) software (Media Cybernetics, Silver Spring, US). The measurement of abutment or protrusion/perimeter in a thyroid lesion was calculated by the average ratio (1/2) on transversal + longitudinal section of a nodule (Figures 1 and 2). For multifocality of suspicious PTMC nodules, we selected the largest nodule to calculate the abutment or protrusion/perimeter ratio. The ratio was graded by values of < 25%, 25%–50%, or > 50%. Capsular abutment is defined as a lack of intervening tissue between PTMC lesions and normal thyroid capsules. Capsular protrusion is defined as disruption of the perithyroidal echogenic line between the primary site of PTMC and the normal thyroid capsule on sonography. The ratio was finally analyzed to assist in predicting cervical lymph node status as confirmed by pathological diagnosis.

Ultrasound features of involved lymph nodes

The sonographic features of involved lymph nodes were based on various criteria, including internal microcalcifications, cystic changes, hyperechogenicity, round shape, loss of hilar echogenicity, vascularity, and size > 5 mm. The locations of lymph nodes in the neck are divided into central and lateral compartments. The central compartment (level VI) is defined as the space between the borders of the bilateral carotid arteries. The lateral compartment extends from the carotid arteries to the medial margins of the trapezius muscle, including levels II, III, IV and V, according to the definitions of the American Head and Neck Society¹². Lymph node skip metastases were defined as negative central cervical LNs but positive ipsilateral cervical LNs existing in some patients with PTMC confirmed *via* histopathological diagnosis.

Statistical analysis

The data were analyzed using SPSS 22.0 software (IBM

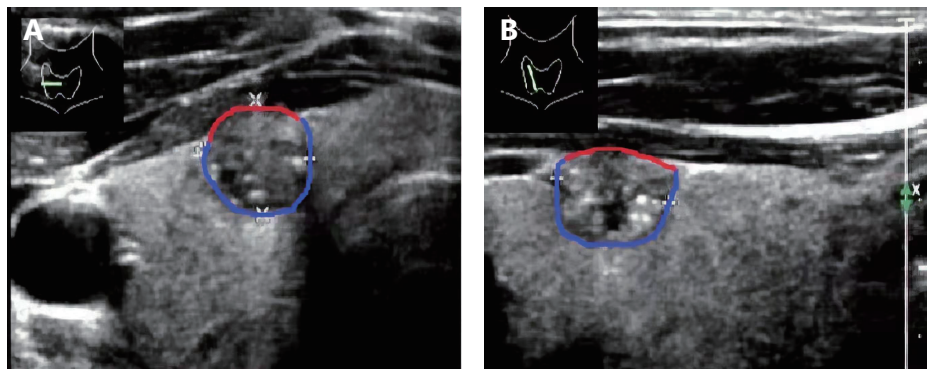


Figure 1 The average ratio of abutment to perimeter (0.33/33%) of a thyroid nodule was calculated on both transverse (A) and longitudinal images (B). Red line: abutment of the nodule and thyroid capsule. Red line+blue line: perimeter of the thyroid nodule.

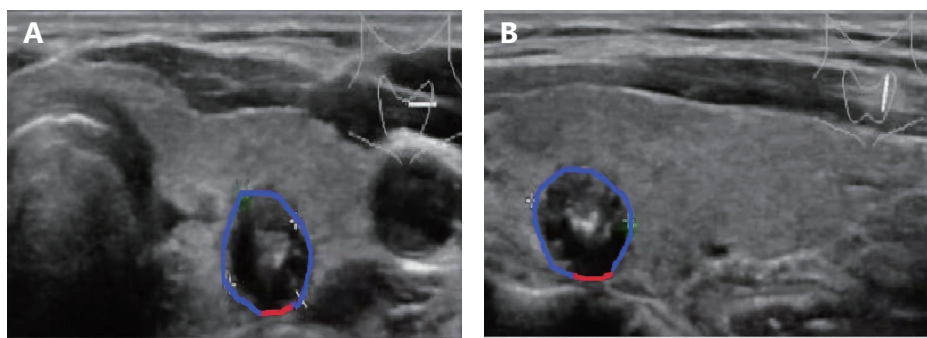


Figure 2 The average ratio of abutment and perimeter (0.12/12%) of a thyroid nodule was calculated on both transverse (A) and longitudinal images (B). Red line: abutment of the nodule and thyroid capsule. Red line+blue line: perimeter of the thyroid nodule.

Company, California, USA). Univariate statistical analysis was performed using the chi square test; multivariate statistical analysis was performed using the unconditional logistic regression model. The receiver operating characteristic curve (ROC) was determined using SPSS software. $P < 0.05$ was considered statistically significant.

Results

We reviewed 710 PTMC patients in the analysis of clinical characteristics of PTMC with cervical lymph node metastases. After a further clinical analysis of two different groups (lymph node metastases or not), we found that there was a significant difference between metastatic and nonmetastatic lymph nodes regarding multifocality and extrathyroidal extension ($P < 0.05$ for these two variables). No significant difference was found in age, gender or Hashimoto thyroiditis in patients with PTMC when predicting cervical lymph node involvement.

To investigate US features of the PTMC primary site for the prediction of cervical ipsilateral lymph node metastases, we analyzed univariate and multivariate logistic regression of

710 PTMC patients. Of these, 218 (30.7%) patients had positive ipsilateral cervical lymph nodes, and 492 (69.3%) had negative nodes; furthermore, 53 (7.5%) patients had positive skip cervical lymph nodes, and 657 (92.5%) had negative nodes. In the univariate model, tumor size (≤ 0.5 and $> 0.5, < 1$ cm), tumor location, calcification, margin and the abutment/perimeter ratio were significantly associated with increased metastatic risk of ipsilateral lymph node involvement (**Table 1**), and tumor size (≤ 0.5 and $> 0.5, < 1$ cm), tumor location, calcification, taller-than-wide dimensions and the abutment/perimeter ratio were significantly associated with skip metastasis of lymph nodes (**Table 2**). In the multivariate regression model, tumor size, tumor location, calcification and the abutment/perimeter ratio were evaluated as independent high-risk factors in the ipsilateral lymph node metastases group (**Table 1**). The tumor size, tumor location, taller-than-wide dimensions, and the abutment/perimeter ratio of the PTMC primary site were independent high-risk factors in the skip lymph node metastases group (**Table 2**).

There is a low sensitivity for the diagnosis of cervical central lymph nodes in PTMC by direct neck

Table 1 Univariate and multivariate analysis of 710 PTMC primary sites with US features for predicting ipsilateral lymph node metastasis

Features	Cases	Patients [n (%)]		χ^2	P	Multivariate model		
		LN(-)	LN(+)			Odds ratio	95% CI	P
Size (cm)				21.611	0.000	2.430	1.479–3.994	0.000
≤ 0.5	159	134 (84.3)	25 (15.7)					
> 0.5, ≤ 1	551	358 (65.0)	193 (35.0)					
Taller-than-wide				2.764	0.099	1.375	0.915–2.066	0.125
< 1	189	140 (74.1)	49 (25.9)					
≥ 1	521	352 (67.6)	169 (32.4)					
Peripheral vascularity				2.680	0.117	1.771	0.810–3.876	0.152
Yes	678	474 (70.0)	204 (30.0)					
No	32	18 (56.3)	14 (43.7)					
Location				38.882	0.000	0.645	0.535–0.778	0.000
Isthmus	17	17 (100.0)	0 (0.0)					
Upper	249	140 (56.2)	109 (43.8)					
Middle	168	118 (70.2)	50 (29.8)					
Lower	276	217 (78.6)	59 (21.4)					
Echogenicity				0.982	0.354	0.939	0.506–1.742	0.842
Hyper or iso-echoic	74	55 (74.3)	19 (25.7)					
Hypo-echoic	636	437 (68.7)	199 (31.3)					
Calcification				27.123	0.000	2.649	1.672–4.197	0.000
No	190	160 (84.2)	30 (15.8)					
Yes	520	332 (63.8)	188 (36.2)					
Margin				7.840	0.005	2.397	0.995–5.775	0.051
Clear	52	45 (86.5)	7 (13.5)					
Unclear	658	447 (67.9)	211 (32.1)					
Abutment/perimeter				8.691	0.004	1.712	1.180–2.483	0.005
≤ 0.25	245	187 (76.3)	58 (23.7)					
> 0.25	465	305 (65.6)	160 (34.4)					

ultrasonography [sensitivity: 48.3%, specificity: 83.7%, area under the curve (AUC): 0.660, 95% CI: 0.619–0.701]¹³ (Figure 3A). For the prediction of level VI lymph node involvement in 486 patients *via* ultrasound features of the primary site, the univariate regression analysis demonstrated the following results: the tumor size (≤ 0.5 and > 0.5, < 1 cm), taller-than-wide dimensions, location, echogenicity, calcification, margin and abutment/perimeter ratio of the PTMC primary site were all significant factors for the prediction of level VI lymph node metastases. The multivariate analysis showed that both calcification and the abutment/perimeter ratio were significant with regard to metastatic cervical level VI lymph nodes ($P = 0.011$ and

0.003, respectively, Table 3).

In addition, Figure 1 shows the ratio of tumor abutment to perimeter described by IPP software, assisting in predictions of lymph node metastases (ipsilateral and level VI). We constructed a cut-off value (25%) as a predictive ratio of US features based on a previous study¹⁴ and our ROC curve results ($P = 0.000$ and 0.003, respectively, Figure 3B and 3C). The sensitivity and specificity of the abutment/perimeter ratio of the thyroid primary site with cut-off value (25%) were 62.1% and 63.3% for level VI LN involvement and 62.2% and 52.5% for ipsilateral LN involvement. (The AUC values were 0.688 with 95% CI: 0.640–0.737 and 0.612 with 95% CI: 0.570–0.654, respectively).

Table 2 Univariate and multivariate analysis of 710 PTMC primary sites with US features for predicting skip metastasis of lymph nodes

Features	Cases	Patients [n (%)]		χ^2	P	Multivariate model		
		LN (-)	LN (+)			Odds ratio	95% CI	P
Size (cm)				11.427	0.000	8.640	2.007–37.192	0.004
≤ 0.5	159	157 (98.7)	2 (1.3)					
> 0.5, ≤ 1	551	500 (90.7)	51 (9.3)					
Taller-than-wide				5.275	0.023	2.572	1.083–6.108	0.032
< 1	189	182 (96.3)	7 (3.7)					
≥ 1	521	475 (91.1)	46 (8.9)					
Peripheral vascularity				1.230	0.289	1.751	0.547–5.606	0.345
No	678	629 (92.8)	49 (7.2)					
Yes	32	28 (87.5)	4 (12.5)					
Location				21.843	0.000	0.531	0.378–0.745	0.000
Isthmus	17	17 (100.0)	0 (0.0)					
Upper	249	219 (88.0)	30 (12.0)					
Middle	168	151 (90.0)	17 (10.0)					
Lower	276	270 (97.8)	6 (2.2)					
Echogenicity				1.391	0.348	1.363	0.388–4.786	0.629
Hyper or isoechoic	74	71 (95.9)	3 (4.1)					
Hypo-echoic	636	586 (92.1)	50 (7.9)					
Calcification				3.977	0.029	1.722	0.759–3.903	0.193
No	190	182 (95.8)	8 (4.2)					
Yes	520	475 (91.3)	45 (8.7)					
Margin				0.234	0.789	0.636	0.167–2.422	0.507
Clear	52	49 (94.2)	3 (5.8)					
Unclear	658	608 (92.4)	50 (7.6)					
Abutment/perimeter				18.421	0.000	7.083	2.488–20.164	0.000
≤ 0.25	245	241 (98.4)	4 (1.6)					
> 0.25	465	416 (89.5)	49 (10.5)					

Discussion

There has been a substantially increasing incidence of thyroid cancer in developed countries, and most cases are PTMC, with an excellent clinical prognosis^{15,16}. However, the prevalence of cervical lymph node metastases of PTMC has been reported to be as high as 24%–64%¹⁷. The sensitivity of both physical examination and ultrasonography in the prediction of cervical central lymph node involvement was found to be as low as 15%–30%, although ultrasound can directly assess lymph node metastases^{13,18}. Our retrospective study aimed to predict cervical lymph node involvement *via* US features of the primary site, increasing the preoperative

selection of high-risk PTMC to assist surgeons in the decision-making process.

We first analyzed the correlation between clinical characteristics and positive cervical lymph node metastasis in PTMC. The clinical results suggested that multifocality and extrathyroidal extension (ETE) were both associated with cervical lymph node metastases (including ipsilateral and central LNs) in 710 PTMC patients. In agreement with a previous study, multifocality and ETE were both considered independent factors of PTMC with the involvement of lymph nodes¹⁹. Then, we investigated the correlation between sonographic features of primary thyroid lesions and cervical lymph node involvement in 710 PTMC cases. The size,

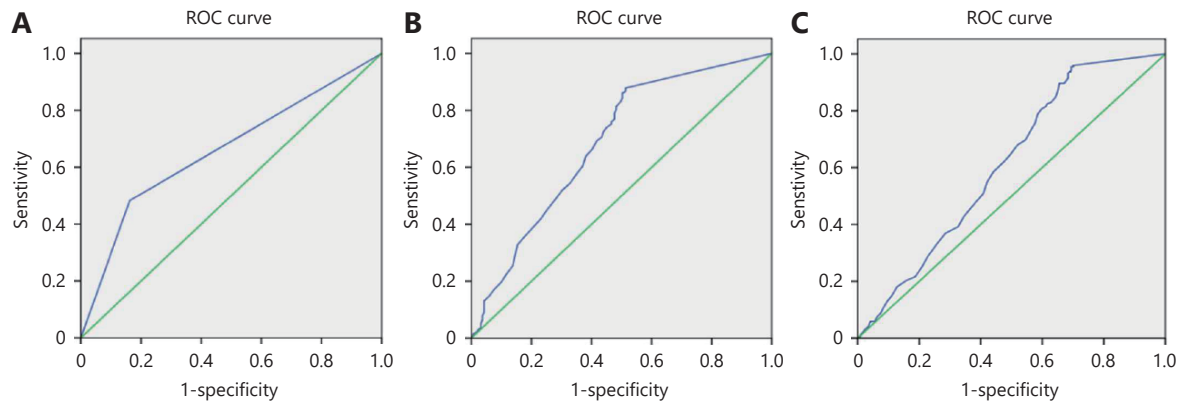


Figure 3 A. The ROC curve showed that ultrasonographic diagnosis of level VI involved lymph nodes with only evaluation of lymph nodes; The ROC curve demonstrated that assessment of level VI (B) or ipsilateral (C) involved lymph nodes *via* abutment/perimeter of primary thyroid lesion.

location and echogenicity, calcification, margin and abutment/perimeter ratio were calculated to be associated with cervical lymph node metastases in the preoperative diagnosis of PTMC. Among these factors, we found that the cut-off value of 5 mm in nodular diameter, location, calcification and the abutment/perimeter ratio of the tumor were significantly associated with positive cervical lymph node metastasis (including ipsilateral and central LNs) of PTMC in the multivariate analysis. The “cut-off” point of the size of PTMC tumors was divided as 5, 6, 7 or 8 mm, but some results failed to identify a statistically significant value, and even a 3 mm tumor was found to be associated with disease recurrence^{4,20}. Therefore, tumor size (> 5 mm), which was preoperatively measured by a sonographer, can assist in the decision to perform surgery.

This is the first study to establish a ratio of tumor abutment/perimeter of the primary site to assess cervical lymph node metastases, providing a visible and feasible tool to evaluate the risk of PTMC metastasis. In this process, sonographers drew a circle along the abutment to compare the measurement with the perimeter of the lesion, which provided useful information for capsular invasion to analyze the possibility of cervical lymph node status. The 1/4 (25%) perimeter of thyroid lesion was established as the cut-off value in our study. The abutment or protrusion of capsular extension was associated with lymph node metastases in PTMC. Kwak et al²¹ and Park et al²² both used an abutment perimeter ratio and calculated a diameter ratio of greater than 50% as the most accurate predictive factor in extrathyroidal extension evaluation. Lee CY et al¹⁴ concluded that the thyroid capsular abutting ratio or the measure capsular protrusion was a useful predictive factor for extrathyroidal extension. Thus, preoperative sonographic

features (abutment/perimeter ratio or ETE) of PTMC primary sites were proven to be a high specificity tool in the assessment of cervical lymph node metastases (including ipsilateral and central LNs) of PTMC.

Because cervical level VI LN involvement is difficult to preoperatively diagnose in PTMC, we speculated that some US features of lesions would be independent factors for the prediction of metastatic lymph nodes in the central cervical area. The results of calcification and the abutment/perimeter ratio (0.25 is cut-off value) were associated with positive lymph nodes in level VI. The abutment/perimeter ratio of 0.25 (1/4) facilitates visible risk prediction in the diagnosis of PTMC primary lesions when sonographic operators are able to draw a 1/4 line along capsular abutment or protrusion of the lesion. These categories will tailor adjuvant treatment regimens and long-term surveillance.

Determination of PTMC lesion calcification was feasible by sonography. Four patterns of calcification were classified as microcalcification, macrocalcification, rim calcification and noncalcification²³. In a previous report, the microcalcification rate was higher in patients with lymph node metastasis than in those without lymph node metastasis. The mechanism of microcalcification formation in PTMC is thought to be through the rapid proliferation of cancer cells, leading to an absence of blood supply and necrosis, which consequently cause calcium accumulation and calcification²⁴. The incidence of microcalcification in PTMC is 35.9%–53.5%, which is associated with a higher number of metastatic neck nodes²³. Calcification of PTMC lesions should be carefully assessed by preoperative sonography²⁵. In addition, we also studied the relationship between US features of PTMC primary sites and skip lymph node metastases. We found that tumor size (≤ 0.5 and > 0.5 ,

Table 3 Univariate and multivariate logistic regression analysis of 486 PTMC primary sites with US features for predicting level VI lymph node metastases

Features	Cases	Patients [n (%)]		χ^2	P	Multivariate model		
		LN(-)	LN(+)			Odds ratio	95% CI	P
Size (cm)				19.495	0.000	1.250	0.922–1.696	0.151
≤ 0.5	131	72 (54.96)	59 (45.04)					
> 0.5, ≤ 1	355	117 (32.96)	238 (67.04)					
Taller-than-wide				3.602	0.063	1.128	0.593–2.095	0.623
< 1	46	25 (54.35)	21 (45.65)					
≥ 1	440	164 (37.27)	276 (62.73)					
Peripheral vascularity				3.631	0.086	1.297	0.721–2.332	0.385
Yes	471	186 (39.49)	285 (60.51)					
No	15	3 (20.00)	12 (80.00)					
Location				9.886	0.020	1.105	0.975–1.254	0.119
Isthmus	22	10 (45.45)	12 (54.55)					
Upper	138	69 (50.00)	69 (50.00)					
Top	118	43 (36.44)	75 (64.56)					
Lower	207	67 (32.37)	140 (67.63)					
Echogenicity				4.234	0.046	1.216	0.772–1.916	0.399
Hyper or iso-echoic	47	25 (53.19)	22 (46.81)					
Hypo-echoic	439	164 (37.35)	275 (62.65)					
Calcification				25.094	0.000	1.461	1.093–1.955	0.011
No	157	91 (57.96)	66 (42.04)					
Yes	329	98 (29.79)	231 (70.21)					
Margin				5.858	0.018	1.111	0.665–1.857	0.688
clear	43	23 (53.49)	20 (46.51)					
unclear	443	166 (37.47)	277 (62.53)					
Abutment/perimeter				23.504	0.000	1.446	1.134–1.844	0.003
≤ 0.25	221	115 (52.04)	106 (47.96)					
> 0.25	265	74 (27.92)	191 (72.08)					

< 1 cm), tumor location, calcification, taller-than-wide dimension and the abutment/perimeter ratio were significantly associated with skip lymph node metastases. Therefore, these US features of the PTMC primary site were risk factors for cervical lymph node metastases, aiding in tailoring PTMC treatment.

Some limitations that should be addressed are as follows. (1) This study is a retrospective analysis of patients from one center, which may contribute to a higher rate of lymph node metastases of PTMC in our series. (2) Future studies should focus on predicting occult lymph node metastases in patients who are sonographically negative. (3) In the future cohort, the clinical node negative or positive status (CN+/-) should be

considered as intercrossed factors in US diagnosis of negative or positive lymph nodes, while investigating the preoperative prediction of cervical lymph nodes in PTMC patients.

Conclusions

Preoperative sonography of thyroid lesions is a practical and useful tool in the diagnosis of PTMC with involved cervical lymph nodes²⁶. We summarized a number of independent ultrasound features, such as lesion size, lesion location, calcification and the ratio of tumor abutment/perimeter of the primary lesion, as independent risk factors in cervical lymph node metastases of PTMC.

Acknowledgments

This work was supported by grants from the National Natural Science Foundation of China (Grant No. 81771852).

Conflict of interest statement

No potential conflicts of interest are disclosed.

References

- Lombardi CP, Bellantone R, De Crea C, Paladino NC, Fadda G, Salvatori M, et al. Papillary thyroid microcarcinoma: extrathyroidal extension, lymph node metastases, and risk factors for recurrence in a high prevalence of goiter area. *World J Surg.* 2010; 34: 1214-21.
- Kwak JY, Kim EK, Chung WY, Moon HJ, Kim MJ, Choi JR. Association of BRAF^{V600E} mutation with poor clinical prognostic factors and US features in Korean patients with papillary thyroid microcarcinoma. *Radiology.* 2009; 253: 854-60.
- Martinez-Tello FJ, Martinez-Cabruja R, Fernandez-Martin J, Lasso-Oria C, Ballestin-Carcavilla C. Occult carcinoma of the thyroid. A systematic autopsy study from Spain of two series performed with two different methods. *Cancer.* 1993; 71: 4022-9.
- Pelizzo MR, Boschin IM, Toniato A, Piotto A, Bernante P, Pagetta C, et al. Papillary thyroid microcarcinoma (PTMC): prognostic factors, management and outcome in 403 patients. *Eur J Surg Oncol.* 2006; 32: 1144-8.
- Cappelli C, Castellano M, Braga M, Gandossi E, Pirola I, De Martino E, et al. Aggressiveness and outcome of papillary thyroid carcinoma (PTC) versus microcarcinoma (PMC): a mono-institutional experience. *J Surg Oncol.* 2007; 95: 555-60.
- Arora N, Turbendian HK, Scognamiglio T, Wagner PL, Goldsmith SJ, Zarnegar R, et al. Extrathyroidal extension is not all equal: implications of macroscopic versus microscopic extent in papillary thyroid carcinoma. *Surgery.* 2008; 144: 942-8.
- Ito Y, Miyauchi A, Kihara M, Higashiyama T, Kobayashi K, Miya A. Patient age is significantly related to the progression of papillary microcarcinoma of the thyroid under observation. *Thyroid.* 2014; 24: 27-34.
- Oda H, Miyauchi A, Ito Y, Sasai H, Masuoka H, Yabuta T, et al. Comparison of the costs of active surveillance and immediate surgery in the management of low-risk papillary microcarcinoma of the thyroid. *Endocr J.* 2016; 64: 59-64.
- Ito Y, Miyauchi A, Inoue H, Fukushima M, Kihara M, Higashiyama T, et al. An observational trial for papillary thyroid microcarcinoma in Japanese patients. *World J Surg.* 2010; 34: 28-35.
- Machado MRM, Tavares MR, Buchpiguel CA, Chammas MC. Ultrasonographic evaluation of cervical lymph nodes in thyroid cancer. *Otolaryngol-Head Neck Surg.* 2017; 156: 263-71.
- Leboulleux S, Tuttle RM, Pacini F, Schlumberger M. Papillary thyroid microcarcinoma: time to shift from surgery to active surveillance? *Lancet Diabetes Endocrinol.* 2016; 4: 933-42.
- Machens A, Hauptmann S, Dralle H. Lymph node dissection in the lateral neck for completion in central node-positive papillary thyroid cancer. *Surgery.* 2009; 145: 176-81.
- Choi JS, Chung WY, Kwak JY, Moon HJ, Kim MJ, Kim EK. Staging of papillary thyroid carcinoma with ultrasonography: performance in a large series. *Ann Surg Oncol.* 2011; 18: 3572-8.
- Lee CY, Kim SJ, Ko KR, Chung KW, Lee JH. Predictive factors for extrathyroidal extension of papillary thyroid carcinoma based on preoperative sonography. *J Ultrasound Med.* 2014; 33: 231-8.
- McLeod DS, Sawka AM, Cooper DS. Controversies in primary treatment of low-risk papillary thyroid cancer. *Lancet.* 2013; 381: 1046-57.
- Chen AY, Jemal A, Ward EM. Increasing incidence of differentiated thyroid cancer in the United States, 1988-2005. *Cancer.* 2009; 115: 3801-7.
- Kim BY, Jung CH, Kim JW, Lee SW, Kim CH, Kang SK, et al. Impact of clinicopathologic factors on subclinical central lymph node metastasis in papillary thyroid microcarcinoma. *Yonsei Med J.* 2012; 53: 924-30.
- Choi YJ, Ji SY, Kook SH, Jung EC, Park YL. Clinical and imaging assessment of cervical lymph node metastasis in papillary thyroid carcinomas. *World J Surg.* 2010; 34: 1494-9.
- Clain JB, Scherl S, Reis LLD, Turk A, Wenig BM, Mehra S, et al. Extrathyroidal extension predicts extranodal extension in patients with positive lymph nodes: an important association that may affect clinical management. *Thyroid.* 2014; 24: 951-7.
- Roti E, Rossi R, Trasforini G, Bertelli F, Ambrosio MR, Busutti L, et al. Clinical and histological characteristics of papillary thyroid microcarcinoma: results of a retrospective study in 243 patients. *J Clin Endocrinol Metab.* 2006; 91: 2171-8.
- Kwak JY, Kim EK, Son EJ, Kim MJ, Oh KK, Kim JY, et al. Papillary thyroid carcinoma manifested solely as microcalcifications on sonography. *Am J Roentgenol.* 2007; 189: 227-31.
- Park JS, Son KR, Na DG, Kim E, Kim S. Performance of preoperative sonographic staging of papillary thyroid carcinoma based on the sixth edition of the AJCC/UICC TNM classification system. *AJR Am J Roentgenol.* 2009; 192: 66-72.
- Oh EM, Chung YS, Song WJ, Lee YD. The pattern and significance of the calcifications of papillary thyroid microcarcinoma presented in preoperative neck ultrasonography. *Ann Surg Treat Res.* 2014; 86: 115-21.
- Johannessen JV, Sobrinho-Simões M. The origin and significance of thyroid psammoma bodies. *Lab Invest.* 1980; 43: 287-96.
- Shi C, Li S, Shi T, Liu B, Ding C, Qin H. Correlation between thyroid nodule calcification morphology on ultrasound and thyroid carcinoma. *J Int Med Res.* 2012; 40: 350-7.
- Gao M, Ge M, Ji Q, Cheng R, Lu H, Guan H, et al. 2017 Chinese expert consensus on the clinical application of serum marker for thyroid cancer. *Cancer Biol Med.* 2018; 15: 468-77.

Cite this article as: Wei X, Wang M, Wang X, Zheng X, Li Y, Pan Y, et al. Prediction of cervical lymph node metastases in papillary thyroid microcarcinoma by sonographic features of the primary site. *Cancer Biol Med.* 2019; 16: 587-94. doi: 10.20892/j.issn.2095-3941.2018.0310